

## REVIEW ARTICLE

# Music and the brain: disorders of musical listening

Lauren Stewart,<sup>1,2,3</sup> Katharina von Kriegstein,<sup>1,3</sup> Jason D. Warren<sup>4</sup> and Timothy D. Griffiths<sup>1,3</sup>

<sup>1</sup>Auditory Group, Newcastle University, Newcastle upon Tyne, <sup>2</sup>Institute of Cognitive Neuroscience,

<sup>3</sup>Wellcome Department of Imaging Neuroscience, and <sup>4</sup>Dementia Research Centre, Institute of Neurology, University College London, London, UK

Correspondence to: Tim Griffiths, Cognitive Neurology Clinic, Newcastle General Hospital, Westgate Road, Newcastle upon Tyne NE4 6BE, UK

E-mail: t.d.griffiths@ncl.ac.uk

**The study of the brain bases for normal musical listening has advanced greatly in the last 30 years. The evidence from basic and clinical neuroscience suggests that listening to music involves many cognitive components with distinct brain substrates. Using patient cases reported in the literature, we develop an approach for understanding disordered musical listening that is based on the systematic assessment of the perceptual and cognitive analysis of music and its emotional effect. This approach can be applied both to acquired and congenital deficits of musical listening, and to aberrant listening in patients with musical hallucinations. Both the bases for normal musical listening and the clinical assessment of disorders now have a solid grounding in systems neuroscience.**

**Keywords:** brain disorders; lesions; listening; music

**Abbreviations:** HG = Heschl's gyrus; MBEA = Montreal battery for the evaluation of amusia; MEG = magnetoencephalography; PAC = primary auditory cortex; PT = planum temporale; SPET = single photon emission tomography

Received February 14, 2006. Revised May 8, 2006. Accepted May 31, 2006. Advance Access publication July 15, 2006.

## Introduction

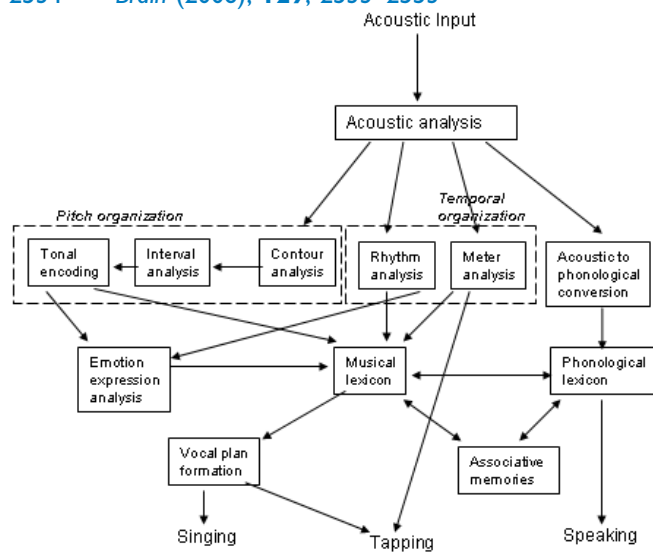
It is now 30 years since the publication of the volume *Music and the Brain* edited by Critchley and Henson (1977). That work still has a place on the bookshelves of many neurologists, as a *vade mecum* of the neurology of the musical brain. During the last 30 years, however, there have been a considerable number of advances in the field, which we consider here.

First, our understanding of the normal musical brain has increased enormously, providing us with a much better understanding of the brain bases for normal musical listening. Many of these advances have been made possible by the application of techniques that demonstrate the functional organization of the musical brain, especially haemodynamic (PET and fMRI) and electrophysiological (EEG and MEG) imaging techniques. Our understanding based on these techniques is evolving all the time, and critically underpins the characterization of musical disorders.

The data from functional imaging can ever be only as good as the theoretical constructs on which the experiments are based: the second major advance in the understanding of musical disorders has been the evolution of the constructs

themselves. Based on these, we now have theoretically motivated instruments for the systematic evaluation of musical disorders: in effect, these instruments are musical equivalents of the better-known aphasia batteries, such as the Aachen Aphasia Test (Huber *et al.*, 1984). Modular schemes for musical perception [e.g. Peretz and Coltheart (2003), see Fig. 1] are both informed by the study of patients (especially the demonstration of dissociated deficits), and allow the development of research tools that can be used in the clinic. These tools have allowed reports of musical disorders to evolve from historical anecdotes to systematic accounts. The development of tools for evaluating different aspects of musical disorders is by no means complete, and clinical evaluation remains a challenge in view of both evolving theoretical accounts and the wide variation in musical experience and training in the general population.

The third major advance is that we can now examine with greater precision the changes in the brain that accompany musical disorders. Thirty years ago detailed anatomical information about lesion patients was only available in



**Fig. 1** Cognitive model of musical processing. Musical analysis is divided into distinct neuropsychological components. The current review considers the neural instantiation of such components, and considers musical listening disorders in terms of deficient or aberrant operation of the components. Based on Peretz I, Coltheart M, 'Modularity of music processing', 2003. Reprinted by permission from Macmillan Publishers Ltd: Nature Neuroscience 6(7): 688–91, copyright 2003.

the rare cases where there was accompanying pathological data. In terms of structural anatomy, lesions can now be defined precisely using structural MRI, whilst the evolution of structural MRI analyses, such as voxel-based morphometry (Ashburner and Friston, 2000) allows the identification of subtle anatomical changes in disorders where the anatomical brain basis is not immediately obvious. This precise characterization of lesions allows us to visualize which parts of the normal cortical network, as identified using functional imaging, have been damaged.

Here, we will describe some of the recent advances in our understanding of normal musical listening that allow a better understanding of disorders, before a systematic review of the disorders themselves. Musical listening is used here to refer not only to the perception of music, but also to what might be referred to as 'musical cognition': the ordering of incoming musical information according to rule-based structures and musical recognition. Apart from musical cognition, another important aspect of musical listening is the triggering of an emotional response, an effect which we will also discuss. We therefore consider a range of deficits in musical listening that includes but is not restricted to the condition of amusia, which is typically defined as a music-specific agnosia.

### Normal musical listening and normal musical brains: some recent advances

Components of normal musical listening have been investigated in a number of studies in which the brain substrates for these are defined by changes in the haemodynamic response

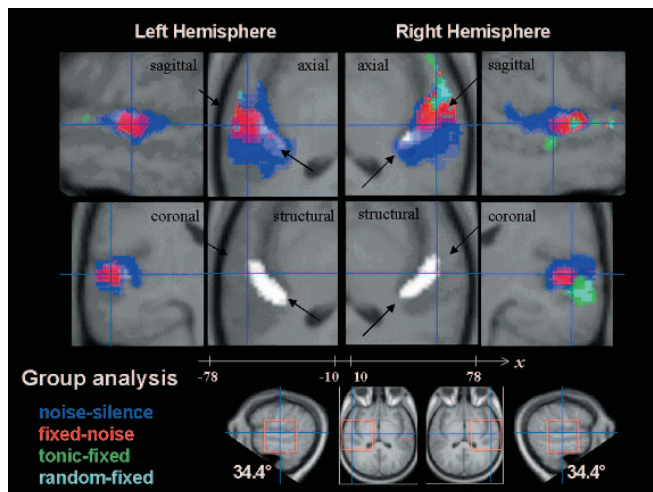
to the mean synaptic firing rate (PET and fMRI) (Logothetis *et al.*, 2001) or the effect of summed graded post-synaptic potentials in dendrites (EEG and MEG) (Wood, 1987). Here we consider these components in order to establish a conceptual framework within which to consider the effect of brain disorders. In addition to these studies, there have been a number of recent advances in our understanding of the structural and functional organization of the brains of musicians, which need to be borne in mind when considering the effects of brain disorders.

### The auditory pathway and cortices

Music, like any sound, music is processed in the ascending auditory pathway to the auditory cortex. That processing includes active analysis of the spectro-temporal structure of the stimulus rather than the simple passive relay of information (Harms *et al.*, 1998; Griffiths *et al.*, 2001). The human auditory cortex is situated in the superior-temporal plane within the Sylvian fissure, which can be best visualized on a tilted axial section, such as those shown in Fig. 2. Cytoarchitectonically defined primary auditory cortex (PAC) is located in the medial part of Heschl's gyrus, (HG) (or the anterior HG in individuals in whom the gyrus is duplicated) running anterolaterally in the plane. There is considerable variation of the relationship between the cytoarchitectonically defined area and the macroscopic boundaries (Rademacher *et al.*, 2001), which needs to be taken into account when considering the effects of lesions defined by macroscopic markings. Lateral to the PAC in HG are secondary auditory cortical areas that may correspond to the human homologues of macaque areas R and RT [see Patterson *et al.*, (2002) for Discussion]. Behind HG lies the planum temporale (PT), which can be described as an auditory association area based on the involvement of this area in the processing of both auditory stimuli and stimuli in other modalities (Griffiths and Warren, 2002).

### Pitch

Pitch has been argued to be a fundamental component of music in every known human culture (McDermott and Hauser, 2005). A critical point about pitch is that it is a percept, rather than a physical attribute of the sound stimulus, and the exact relationship between the stimulus attributes and the percept is still debated (Plack *et al.*, 2006). Studies where the strength of perceived pitch has been varied by varying the fine temporal structure of sound have demonstrated prominent responses that reflect activity in secondary cortex in lateral HG rather than primary cortex (Gutschalk *et al.*, 2002; Patterson *et al.*, 2002). Another study (Penagos *et al.*, 2004), where the pitch strength was altered by varying the spectrum, demonstrated a similar mapping of pitch strength to secondary cortex, suggesting the possibility of a 'pitch centre' in lateral HG where there is encoding of the percept as opposed to the stimulus properties. Interestingly, recent recording work on



**Fig. 2** Pitch processing in superior-temporal cortex. The lower centre panels show an axial structural MRI for nine subjects tilted by  $34.4^\circ$  to show the superior-temporal plane. HG shown in white runs anterolaterally within the superior-temporal plane. Changes in brain activity as assessed by blood-oxygen-level-dependent response are shown in colour. Noise stimuli, compared to rest, activate large regions of the superior-temporal plane (shown in blue) including medial HG containing primary cortex, lateral HG containing secondary cortex, PT posterior to HG and planum polare anterior to it. Pitch stimuli, compared to noise stimuli with a similar spectrum, produce peak activation in secondary cortex in lateral HG (shown in red). Sequences of variable pitch (tonal melody in green or random-pitch sequence in cyan), compared to a monotonous sequence, produce right-lateralized activation in lateral HG, posterior superior-temporal gyrus, and planum polare. The data are consistent with hierarchical mechanisms for pitch analysis with a 'pitch centre' that represents the pitch of individual notes in lateral HG and more distributed representation of pitch sequences in superior-temporal lobe. Reprinted from Patterson RD, Uppenkamp S, Johnsrude IS, Griffiths TD. The processing of temporal pitch and melody information in auditory cortex. *Neuron* 2002; 36: 767–76, copyright 2002, with permission from Elsevier.

the primates can also be interpreted in terms of the existence of a 'pitch centre' in secondary auditory cortex (Bendor and Wang, 2005)

In music, pitch is used to construct melodies (patterns of pitch over time), chords (the simultaneous presentation of more than one pitch) and harmonies (the simultaneous presentation of more than one melody). Bilateral brain activation during the analysis of pitch sequences occurs in the anterior and posterior superior-temporal lobes with a degree of right lateralization (Griffiths *et al.*, 1998; Patterson *et al.*, 2002) (see Fig. 2). In these passive listening experiments, no difference was demonstrated between random-pitch sequences and tonal melodies. In experiments where subjects were required to follow a melody and compare the pitch at different points, additional activation was demonstrated in the right frontal operculum (Zatorre *et al.*, 1994). In Western tonal music, melodies are constructed using keys where only certain notes are allowed within the octave. Activity has been demonstrated in the mesiofrontal cortex that

depends on both the key and the history of keys visited in a piece (Janata *et al.*, 2002). Other studies [reviewed in Koelsch and Siebel (2005)] have demonstrated responses in the lateral frontal lobes in the region of Broca's area and its right homologue to deviation from an expected chord (based on tonal context). A study that examined the activation in the comparison between orchestral music and temporally 'scrambled' music (Levitin and Menon, 2003) also showed frontal activation bilaterally in the pars orbitalis area.

The picture that emerges from these studies of pitch is that the normal perception of pitch and simple pitch sequences involves networks that include the auditory cortices and adjacent areas in the superior-temporal lobes. These perceptual features of music are shared with other sounds, such as speech, and there is considerable overlap in the activation in temporal lobe areas produced by speech and music (Price *et al.*, 2005). In the future, differences between speech and musical processing in these areas may emerge based on patterns of connectivity that can be demonstrated by techniques, such as dynamic causal modelling in fMRI (Friston *et al.*, 2003) and coherence analysis in EEG and MEG (Patel and Balaban, 2000). In contrast to perceptual analysis, active rule-based analysis of simultaneous and sequential pitch structures (harmony and melody) that depends upon exposure requires much more distributed processing involving the frontal lobes. The data seem to favour the existence of music-specific cortical networks for such cognitive analysis and MEG experiments (Patel and Balaban, 2000) have demonstrated that the coherence between widely spaced elements of these networks is greatest during the processing of pitch sequences with a pitch contour that is similar to music. However, our understanding of the brain basis for more cognitive aspects of pitch analysis, such as tonal analysis, is still at a very early stage.

## Timbre

A further fundamental aspect of musical structure is timbre, a perceptual property that allows us to distinguish between different instruments. In German, timbre translates to 'Klangfarbe' (literally 'sound-colour'), emphasizing the extent to which this property of sound can be used to express different parts of the musical 'palette'. Timbre is important in the separation of musical 'streams' (Bregman, 1990) and has been used as a musical device in the work of Schönberg and Webern who composed *Klangfarbenmelodien* (literally, 'sound-colour melodies') based on timbral sequences. Timbre has been shown, using the technique of multidimensional scaling (McAdams and Cunible, 1992; Caclin *et al.*, 2005), to have a number of dimensions that can be associated with different physical properties of the stimulus, related to aspects of the spectral or temporal structure. In a study where several dimensions of timbre were altered simultaneously, bilateral changes in activity were observed in the posterior superior-temporal lobes (Menon *et al.*, 2002). Studies focusing on the analysis of the spectral dimension

of timbre also demonstrated involvement of the posterior superior-temporal lobes, in addition to right-lateralized activity in the superior-temporal sulcus (Warren *et al.*, 2005). Analysis of the voice, the prototypical musical instrument, has also been shown to be associated with activity in the right superior-temporal sulcus (Belin *et al.*, 2000).

### Temporal structure

The brain substrates underlying analysis of the temporal organization of music (rhythm and metre) have been less thoroughly investigated compared with those that underlie pitch perception. Several studies have used simple patterns of beats without a particular musical context. A PET study (Penhune *et al.*, 1998) demonstrated activity in the lateral cerebellum and basal ganglia during the reproduction of a rhythm. A functional MRI (fMRI) study (Sakai *et al.*, 1999) based on the comparison of sequences without motor reproduction suggested a different representation of sequences with time intervals that were in integer ratios compared with non-integer ratios. The former type of ratio is more common in music, and produced increased activity in the anterior lobe of the cerebellum. A recent study (Xu *et al.*, 2006) showed activation of cerebellar areas during both perception and performance of temporal sequences. These studies, showing activation in motor structures, suggest the possibility of a motor theory of rhythm perception, as a parallel to the motor theory of speech perception (Lieberman and Mattingly, 1985) whereby our perception of rhythm might depend on the motor mechanisms required for its production. Behavioural work in infants (Phillips-Silver and Trainor, 2005) suggests an interaction between information about body movement and perceived rhythm, where there is an alteration of perceived rhythm due to imposed body movement (bouncing). The functional imaging studies above emphasise differences between the perceptual bases of temporal and melodic structure. However, a study in which both dimensions were present, but subjects performed either a melodic or a temporal task showed a very similar network of activation in the posterior superior-temporal lobes, cerebellum and basal ganglia (Griffiths *et al.*, 1999).

### Emotion

The above studies of the normal brain have considered different aspects of music by looking at its component parts, but it can be reasonably argued that the musical listening experience is an emergent property that is greater than the sum of its parts. One example would be the emotional transformation (the ‘shiver down the spine’) that many people experience while listening to certain pieces of music. This is an intense, involuntary physiological response, which is triggered by the emotional response to different music in different individuals. An elegant experiment using PET (Blood and Zatorre, 2001) examined the brain basis for this and showed activation for the contrast between sounds that produced ‘shivers’ and those that did not. The contrast

demonstrated activity, not in the superior-temporal lobe areas activated during melody analysis, but in areas previously implicated in other intensely pleasurable activities, including the ventral striatum, amygdala, and orbitofrontal cortex. An fMRI study contrasting unpleasantly transformed music with pleasant music (Koelsch *et al.*, 2006) also demonstrated activity in mesolimbic areas including the amygdala, in addition to activity in auditory cortex that was not shown in the study by Blood and Zatorre (2001). The study by Koelsch *et al.*, (2006) used pitch shifts of melodies to achieve a dissonant sound with control over the long-term spectrum and temporal envelope of the stimulus. An earlier PET study (Blood *et al.*, 1999) that examined the effect of manipulating consonance and dissonance on brain activity, also showed activation in mesolimbic areas, as did an fMRI study in which non-musicians listened passively to unfamiliar music, which they later rated as pleasant (Brown *et al.*, 2004). The difference in activity in auditory cortex in these studies may reflect details of the paradigms or techniques, but the common variation in mesolimbic activity associated with emotion in music is fundamentally different to the activation during manipulations of other musical components.

### Specialization of the musical brain

One problem with the assessment of musical disorders is the difficulty in defining a ‘normal musical brain’. Whilst aphasia schedules can reasonably assume a degree of uniformity in education, where most people are trained to a certain level, that assumption cannot be made with respect to music. An early study based on differences in melody discrimination depending on whether they were presented to the left or the right ear (Bever and Chiarello, 1974) suggested differences in brain lateralization between musicians and non-musicians. A number of neuro-imaging studies have demonstrated structural differences in the brains of musicians in auditory (Schneider *et al.*, 2002), motor (Amunts *et al.*, 1997), somatosensory (Gaser and Schlaug, 2003), superior parietal (Gaser and Schlaug, 2003), callosal (Schlaug *et al.*, 1995a) and cerebellar (Hutchinson *et al.*, 2003) areas. Longitudinal studies have demonstrated functional brain reorganization after even short periods of musical training (Gaab *et al.*, 2006; Stewart *et al.*, 2003), although the extent to which these changes endure after training is unknown. Studies of the subpopulation of musicians who possess absolute pitch (AP) suggest differences in brain organization from those without the ability. Structural studies using both region-of-interest approaches (Schlaug *et al.*, 1995b) and interrogation of the whole brain with voxel-based morphometry (Luders *et al.*, 2004) both suggest increases in leftward asymmetry in the PT associated with AP. Functional imaging (Zatorre *et al.*, 1998) demonstrates different networks of activity during pitch interval judgement in AP: subjects without AP show activity in right inferior frontal areas, which can be plausibly argued to reflect a form of working memory for pitch, whilst AP possessors engage



left dorsolateral frontal areas that may reflect associative analysis. Critical to the interpretation of structural and functional differences in skilled performers is the question of whether such differences are the result of musical training or whether whether such differences may contribute to an individual's decision to learn music, or to persist in learning music when others may give up. In partial favour of the argument that these differences arise from, rather than enable, skill development is the demonstration that the extent of the structural difference often correlates with the age of onset of musical training (Amunts *et al.*, 1997) or intensity of practice (Bengtsson *et al.*, 2005; Gaser and Schlaug, 2003). However, only longitudinal studies in which differences in brain structure can be measured in the same individuals as learning proceeds will be able to unequivocally demonstrate the differential influence of nature versus nurture.

### **A framework for consideration of disorders of musical listening**

The above discussion is intended to suggest some general principles regarding the neural bases of musical analysis by the brain: for a more detailed account the reader is referred to Peretz and Zatorre (2005). What emerges from such a consideration is the principle that different components of music (pitch, melody, rhythm, timbre and emotion) are underpinned by different psychological mechanisms and neural substrates. This principle is most clearly evident in the case of pitch and melody: the evidence suggests a scheme in which the perception of pitch and simple patterns of pitch is supported by mechanisms in the auditory cortices, whilst cognitive analysis of patterns within the pitch and time-domains requires more distributed networks including the frontal cortex.

In view of the discussion above, any attempt to produce a systematic framework within which to consider disorders of musical processing may seem doomed. It can be reasonably argued that no universal and robust assessment could ever be applied to all patients, taking account of the many diverse components of musical listening and emotional response, and the large variation in musical experience and training between subjects. However, clinical disorders can be approached systematically even if assessment is necessarily limited to particular domains of musical processing. In the next section, 'Acquired deficits in musical listening', we apply the systematic perspective developed above to published cases of acquired disorders of musical listening. In presenting the data, we recognize that these studies differ widely in the premorbid musical expertise of the patients described, the musical domains studied and the methods of assessment used. We then consider cases of developmental amusia and musical hallucinations within a similar framework.

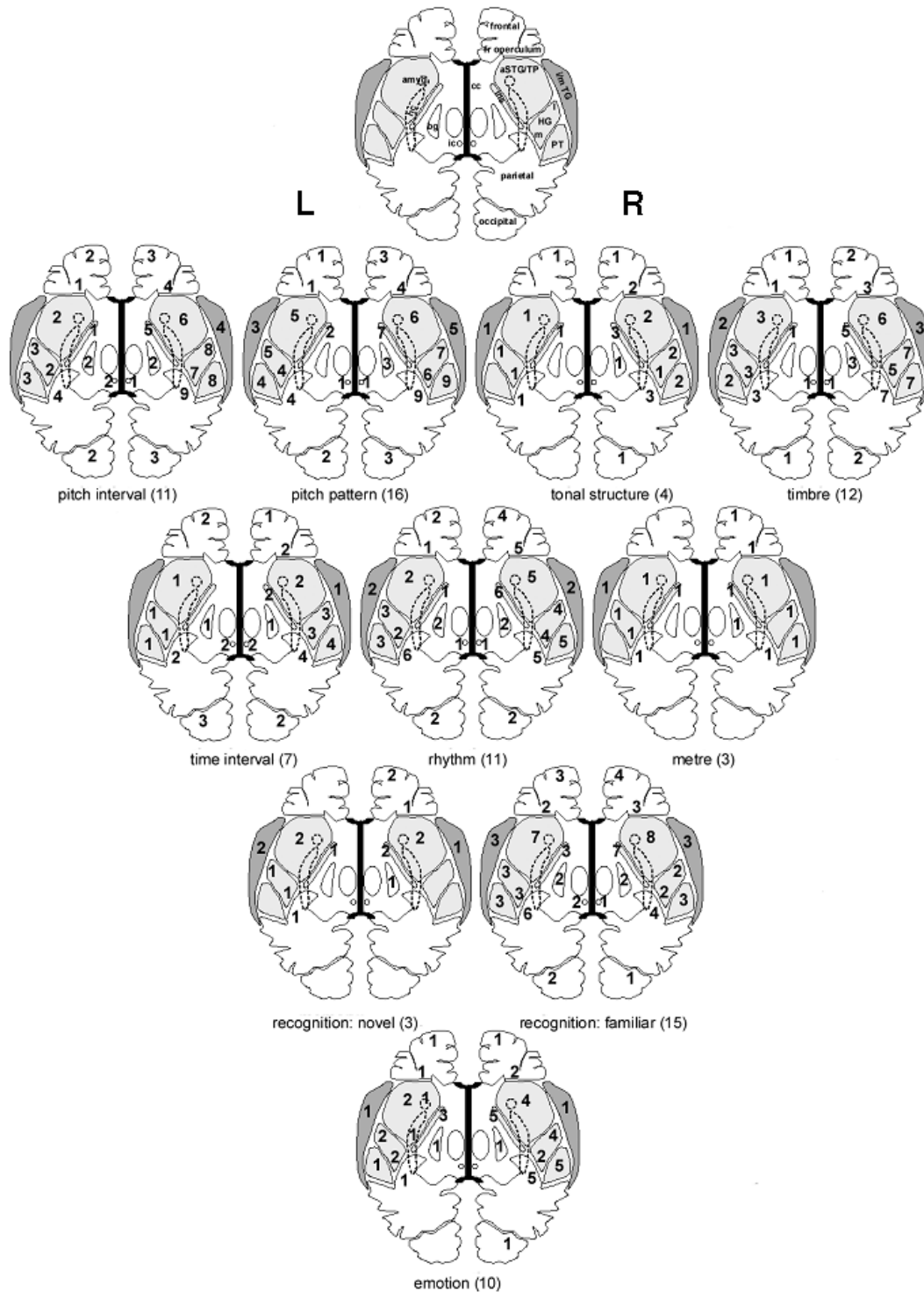
### **Acquired deficits in musical listening**

The clinical neurologist is generally concerned with understanding and characterizing deficits as they present in the

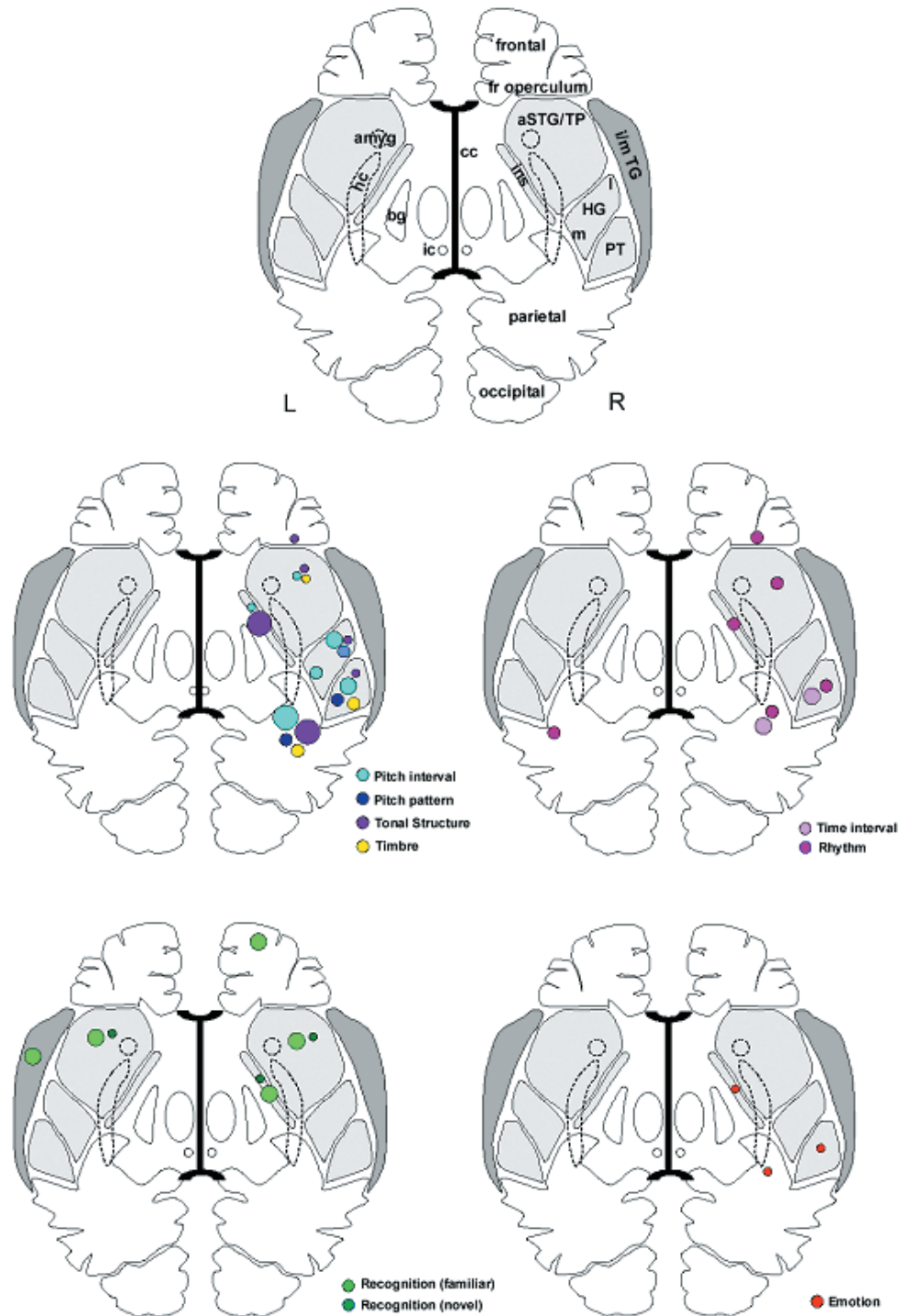
individual patient with an acquired brain lesion. The study of patients with musical deficits is over a century old (see Critchley and Henson, 1977) and the clinical case study remains central to understanding the musical brain. Only by studying the behavioural correlates of focal brain damage is it possible to identify critical anatomical substrates for particular musical functions within the distributed brain networks identified by functional imaging of the normal brain. Here we present a comprehensive overview of case studies of acquired disorders of musical listening, with the aim of establishing general patterns that hold across the literature on these disorders. Our primary objective is to characterize the brain basis for the clinical symptomatology of musical listening disorders. However, this is a challenging enterprise with a number of limitations.

The first set of limitations applies to any cognitive neuropsychological study. Naturally occurring brain lesions are rarely circumscribed, with locations dictated by pathological processes, especially vascular anatomy. The pattern of deficits frequently changes over time, and premorbid behavioural measures are generally lacking. Assessment and interpretation of particular functions may also be confounded by co-existing deficits (e.g. aphasia). Focal brain lesions occur within functional networks. Although neuropsychological evidence can be used to infer that a particular region is critical for a function, it should be noted that the affected region may not be sufficient, in and of itself, to support the function, which may depend equally on other regions within a broader network. Accordingly, maps of the effects of lesions (such as those in Figs 3 and 4) should not be equated with maps of the whole network required for a particular function. Rather, they represent the critical components of normal networks. We have already suggested by studies described in the section 'Normal musical listening and normal musical brains: some recent advances'. We suggested in the same section that early musical perceptual analysis might be a product, not only of analysis within particular cortical areas, but of patterns of connectivity between cortical areas that are commonly engaged during the analysis of different types of sound. With respect to lesions, it is worth bearing in mind that these might disconnect areas involved in different processes, as well as damaging the areas themselves.

Further limitations are specific to music. The effect of the lesion depends on the premorbid level of musical competence and awareness, which varies widely in the general population. The level of musical training influences the kinds of assessment that can be performed, and musical training may be associated with structural differences and functional brain organization. The assessment of musical functions is intrinsically difficult: while tools exist for measuring and calibrating for premorbid musical ability and experience [e.g. Grison's Levels of Musical Culture (Grison, 1972)], the Barbizet scale of Premorbid Musical Ability [cited in Prior *et al.* (1990) and the battery of Wertheim and Botez (1961)], these tools have not been used systematically. Music perceptual abilities are not



**Fig. 3** Sites of brain lesions in individual cases of musical listening disorders. Eleven cartoons are shown, each depicting the brain in a schematic axial view that includes all key anatomical areas involved in music listening (identified on the top cartoon); the corpus callosum (black), superior-temporal plane (light grey) and middle/inferior temporal gyri (dark grey areas, in exploded view) are coloured for ease of identification. The ten musical functions analysed in Supplementary Table 1 are each assigned to a separate cartoon. The number of cases in which a deficit in that function is identified are shown on the figure, and the total number of cases in which that function was assessed is shown in parentheses below each figure. amyg = amygdala; aSTG = anterior superior-temporal gyrus; bg = basal ganglia; cc = corpus callosum; fr = frontal; hc = hippocampal; HG = Heschl's gyrus; ic = inferior colliculi; i = inferior; ins = insula; l = lateral; m = medial; thal = thalamus; PT = planum temporale; TG = temporal gyrus.



**Fig. 4** Critical brain substrates for musical listening disorders across studies. Five cartoons are shown, each depicting the brain in a schematic axial section that includes all key anatomical areas involved in music listening (identified on the top cartoon); the corpus callosum (black), superior-temporal plane (light grey) and middle/inferior temporal gyri (dark grey areas, in exploded view) are coloured for ease of identification. Musical functions analysed in Supplementary Table 1 have been grouped as follows: pitch processing (pitch interval, pitch pattern, tonal structure, timbre); temporal processing (time interval, rhythm); musical memory (familiar and novel material); and emotional response to music. Each group of functions is assigned to a separate cartoon; individual functions are identified to the right of the corresponding cartoon. Raw data from Supplementary Table 1 have been thresholded; the presence of a coloured circle corresponding to a particular function in a region indicates that at least 50% of studies of the function implicate that region. The size of each circle is scaled according to the proportion of studies of the function implicating that region (see text). Metre is not represented as no brain area was implicated in 50% or more of cases. amyg = amygdala; aSTG = anterior superior-temporal gyrus; bg = basal ganglia; cc = corpus callosum; fr = frontal; hc = hippocampal; HG = Heschl's gyrus; ic = inferior colliculi; i = inferior; ins = insula; l = lateral; m = medial; thal = thalamus; PT = planum temporale; TG = temporal gyrus.

routinely assessed in a neuropsychological examination, and require at least some level of musical sophistication to administer and interpret. In research settings, the Montreal Battery for the Evaluation of Amusia [MBEA (Peretz *et al.*, 2003)] offers the advantages of simplicity, comprehensiveness and the availability of normative data, but many other batteries have been used to assess individual clinical cases (see Appendix). While the format of many tests is broadly similar (e.g. same/different tasks with pairs of melodies) the details may differ in ways that are important for interpretation.

The identification of cases of acquired disorders of musical listening based on symptom profiles in individual patients constitutes the traditional ‘symptom-led’ approach of the clinical neurologist. This approach is, however, subject to several fundamental criticisms (Zatorre, 1985). The method of ascertainment is intrinsically biased, since cases may be identified due to a particular pattern of deficits, or because the patient was previously a professional musician and therefore highly aware of the deficit. Individual cases are anatomically and clinically heterogeneous making it difficult to draw more general conclusions about the necessary brain substrates that are common to all individuals.

For these reasons, an alternative approach to the clinical study of musical deficits has been advocated, based on the study of cases selected on the basis of a particular brain lesion, rather than clinical symptoms: the ‘lesion-led’ approach. Using this approach, groups of patients in whom the locus and extent of brain damage are relatively homogeneous are assessed systematically on tests of musical perception. This approach has been used most widely in patients who have undergone temporal lobectomy for the relief of intractable epilepsy. By classifying patients according to the side and extent of the resection, it is possible to assess the role of each cerebral hemisphere and particular cortical areas within each hemisphere in particular musical functions. It is also possible to test patients before and after surgery (Milner, 1962; Shankweiler, 1966; Kester *et al.*, 1991) so that individuals serve as their own controls, thereby minimising the effects of inter-individual variability inherent to group comparisons.

However, the lesion-led approach itself has significant limitations. Resections for epilepsy sample only a restricted fraction of the brain (chiefly the anterior temporal lobe), because of the nature of the disease process and the need to protect eloquent brain areas. This anatomical emphasis also occurs in naturally occurring (chiefly, vascular) lesions, but these predominantly affect different areas in the posterior temporal lobe and beyond. Moreover, patients with intractable epilepsy are likely to have longstanding alterations of cortical organization, and the relevance of such changes to the organization of the healthy brain is difficult to determine. The assessments are biased toward easily measured perceptual deficits, whilst the principal complaint of symptomatic patients is often emotional: they no longer enjoy music. The issue of behavioural relevance is fundamental to lesion-led studies: the identification of a

deficit by a process of systematic search is of quite different significance to the same deficit volunteered as a clinical symptom. Comparisons between the two literatures in order to draw conclusions about the role of particular brain regions in particular musical functions must therefore be made with care. The information about musical listening deficits obtained from the symptom-led and lesion-led literature is complementary, both anatomically and functionally. In this review, lesion-led studies are therefore considered as an adjunct to our primary focus on symptomatic disorders of musical listening.

## Selection and analysis of clinical cases in this review

Table 1 lists published clinical case studies selected for analysis on the basis of the following criteria: presentation with a symptomatic musical deficit (of musical listening or production) or a general auditory agnosia including a musical deficit; documentation of a systematic and objective evaluation of musical listening; and an adequate anatomical description of the lesion based on brain imaging (MRI, CT or angiography), or neuropathology. Table 2 lists published series of patients with lesions that meet all criteria except the presence of a symptomatic deficit. Supplementary Tables 1 and 2 characterize these cases in greater systematic detail. All cases meeting our criteria were analysed in terms of lesion location, and the components of musical listening based on contemporary models.

In the symptom-led literature (Table 1 and Supplementary Table 1), lesions have been analysed according to aetiology, side and specific brain regions affected, based on the brain images supplied or the description of the imaging or neuropathology in the original reports. The analysis by

**Table 1** Acquired symptom-led reports

Brust (Case 2) (1980)	Mazzucchi <i>et al.</i> (1982)
Confavreux <i>et al.</i> (1992)	Mendez and Geehan (MS) (1988)
Di Pietro <i>et al.</i> (2004)	Patel <i>et al.</i> (CN) (1998)
Eustache <i>et al.</i> (Cases 1 and 2) (1990)	Patel <i>et al.</i> (IR) (1998)
Fries and Swihart (1990)	Peretz <i>et al.</i> (CN) (1994)
Fujii <i>et al.</i> (1990)	Peretz (CN) (1996)
Griffiths <i>et al.</i> (1997)	Peretz <i>et al.</i> (IR) (1997)
Griffiths <i>et al.</i> (2004)	Peretz <i>et al.</i> (IR) (1998)
Griffiths <i>et al.</i> (2006)	Peretz and Gagnon (IR) (1999)
Habib <i>et al.</i> (1995)	Peretz <i>et al.</i> (IR) (2001)
Hattiangadi <i>et al.</i> (2005)	Piccirilli <i>et al.</i> (2000)
Hofman <i>et al.</i> (1993)	Satoh <i>et al.</i> (2005)
Johannes <i>et al.</i> (1998)	Spreen <i>et al.</i> (1965)
Johkura <i>et al.</i> (1998)	Tanaka <i>et al.</i> (1987)
Kohlmetz <i>et al.</i> (2003)	Terao <i>et al.</i> (2005)
Lechevalier <i>et al.</i> (1984)	Tramo <i>et al.</i> (MS) (1990)
Levin and Rose (1979)	Tramo <i>et al.</i> (MS) (2002)
Mavlov (1980)	Uvstedt (Case 9) (1937)
Mazzoni <i>et al.</i> (1993)	Wilson <i>et al.</i> (2002)

See Supplementary Table 1 for comprehensive description of reports.



**Table 2** Acquired lesion-led reports

Resection cases	Stroke/other type of lesion
Gosselin <i>et al.</i> (2005)	Ayotte <i>et al.</i> (2000)
Johnsrude <i>et al.</i> (2000)	Grossman <i>et al.</i> (1981)
Kester <i>et al.</i> (1991)	Peretz (1990)
Liegeois-Chauvel <i>et al.</i> (1998)	Prior <i>et al.</i> (1990)
Milner (1962)	Robin <i>et al.</i> (1990)
Samson and Zatorre (1988)	Samson <i>et al.</i> (2001)
Samson and Zatorre (1991)	Schuppert <i>et al.</i> (2000)
Samson and Zatorre (1992)	Shapiro <i>et al.</i> (1981)
Samson and Zatorre (1994)	Sidtis and Volpe (1988)
Samson <i>et al.</i> (2001)	Tramo and Bharucha (1991)
Samson <i>et al.</i> (2002)	
Shankweiler (1966)	
Warrier and Zatorre (2004)	
Zatorre (1985)	
Zatorre (1988)	
Zatorre and Halpern (1993)	
Zatorre and Samson (1991)	

See Supplementary Table 2 for comprehensive description of reports.

region includes a detailed subdivision of the temporal lobe including auditory cortical areas implicated in normal musical listening: the temporal lobe is divided into medial HG (containing PAC), lateral HG (secondary auditory cortex), PT, anterior STG/temporal pole, insula, middle and inferior temporal gyri, and mesial temporal lobe and amygdala. Regions outside the temporal lobe including areas implicated in normal musical listening in the section ‘Normal musical listening and normal musical brains: some recent advances’ are divided into the ascending auditory pathways (inferior colliculi, auditory thalamus and auditory radiation), inferior parietal lobe, frontal operculum, other frontal lobe areas, basal ganglia, occipital lobe, cerebellum and corpus callosum. Most studies included in the lesion-led literature summary (Table 2 and Supplementary Table 2) describe temporal lobectomy series; the right hand section of that table includes studies where patients with other patterns of brain damage (chiefly, stroke) are tested for musical perception. The latter studies lack the anatomical precision of the temporal lobectomy studies, because patients are assigned to rather broadly defined anatomical groups (e.g. right or left stroke). However, we include them because of their utility in addressing questions of laterality.

In Supplementary Tables 1 and 2, pitch analysis (pitch interval, pitch pattern and tonal structure) and temporal analysis (time interval, metre and rhythm) are arranged hierarchically. Timbre is separated as a perceptual property distinct from pitch and the timing of notes. Recognition memory for novel melodies or familiar music is included as a separate category. In some cases, a patient’s performance is judged by the authors to be impaired even in the absence of formal comparison with control subjects: in such cases, we classified patients’ performance as ‘below expected’.

Although the emotional response to music is rarely tested, it is often part of the presentation and we have therefore included subjective report as a measure of emotional processing.

Aside from the data obtained via musical testing, several other abilities are relevant to interpretation of the clinical literature. The patient’s premorbid level of musical competence is included where described. The interval between the cerebral event and the time of musical assessment is indicated, since substantial recovery can occur during this interval. Musical listening deficits may associate with or dissociate from linguistic ability and the ability to perceive other types of complex sounds, (such as environmental sounds); we therefore also include measures of language and environmental sound perception where available. Though data are available for only a proportion of cases, pure tone audiometry is of relevance in order to demonstrate that musical perceptual problems are not the result of peripheral hearing loss, and audiometric findings are therefore included where provided.

Our analysis of the symptom-led literature on acquired disorders is presented graphically in Figs 3 and 4. The distribution of deficits across case studies has been rendered on template brain schematics representing each of the key anatomical regions involved in musical listening. In Fig. 3, the distribution of deficits is shown separately for each musical function. In Fig. 4, the data have been grouped according to the broad functional hierarchies outlined above: pitch, timbre, temporal information, musical memory and emotion. In addition, a transformation procedure has been applied to generate a visual analogue of the relative importance of each region for particular musical functions. The data were first thresholded so that a given function is only ascribed to a particular brain region if at least 50% of studies of that function implicate that region. Data meeting this threshold criterion are represented as coloured circles. In each brain region, the size of each circle is scaled according to the proportion of studies that implicate that region for a particular function. The distribution of coloured circles in Fig. 4 therefore indicates the anatomical emphasis of lesions producing different types of musical listening deficits, while the size of the circles indicates the relative extent to which particular brain areas contribute to each deficit.

## General principles

Taken together, the case reports analysed here (Supplementary Tables 1 and 2 and Figs 3 and 4) suggest that the breakdown of musical listening in the lesioned brain follows certain basic principles. It is clear that a deficit in musical listening does arise as a consequence of a central disturbance of auditory processing: of all the cases in Supplementary Table 1 that included audiometry, none had a musical listening deficit that could be attributed to a peripheral hearing deficit. The brain lesions that produce deficits in musical listening are widely distributed (Fig. 3), but with

a preponderance of locations in the right hemisphere (Fig. 4). The results from functional imaging studies of musical listening reviewed above implicate a bilateral network of areas involved in musical listening, but the results from acquired cases of amusia suggest that right hemispheric structures, including superior-temporal cortex (principally non-PAC), and other areas including the insula and frontal lobe are the necessary components of this network. However, even though right-sided lesions are more commonly associated with deficits in pitch and other domains (Fig. 4), left sided lesions can also, though less commonly, produce deficits in these aspects of musical listening (Fig. 3). It should be borne in mind that the preponderance of right hemispheric lesions associated with musical listening deficits may, at least partially, reflect a sampling bias: individuals with left hemisphere damage are often aphasic and testing of non-linguistic skills is often difficult and rarely a priority.

The majority of cases are attributable to cerebrovascular events, though other pathologies, such as focal cerebral degeneration ('progressive amusia') are represented (Confavreux *et al.*, 1992). Because of the nature of these lesions, musical listening disorders are rarely 'pure' (Supplementary Table 1): over half the cases are associated with disorders of speech perception, and approximately a third of the cases with disorders of environmental sound perception. In most cases available data on speech processing are limited, preventing clear comment about the general association of directly related speech deficits (e.g. perceptual dysprosody) or other deficits in the speech domain. There is some evidence from Supplementary Table 1 to suggest that the earlier stages of an acquired deficit in musical listening (e.g. less than one year after onset) tend to be accompanied by more deficits in listening to other classes of sounds: this in turn suggests that a disorder in musical listening can emerge as an isolated deficit following the recovery phase of a more generalized auditory agnosia.

Within the domain of music, it is rare that the effects of lesions are functionally specific. Figs 3 and 4 show that many areas are implicated in more than one function. However, it is clear that the necessary bases for music processing are separable: relatively isolated deficits of pitch (Peretz *et al.*, 1994), temporal (Mavlov, 1980), timbral (Kohlmétz *et al.*, 2003), mnemonic (Peretz, 1996) and emotional (Griffiths *et al.*, 2004) processing have all been described. More fine-grained dissociations also occur: for instance, between pitch interval and pitch contour (Liegeois-Chauvel *et al.*, 1998; Peretz, 1990) and between rhythm and metre (Di Pietro *et al.*, 2004; Wilson *et al.*, 2002). The data suggest a general scheme in which any brain substrate identified as critical for a particular musical function will have relative rather than absolute specificity for that function. With this in mind, the following sections consider candidate brain substrates for each of these musical functions, based on the symptom-led and lesion-led evidence amassed in Supplementary Tables 1 and 2 and summarized in Figs 3 and 4. Where possible, this evidence is related to organizational

schemes emerging from functional imaging studies in normal subjects, in order to show how lesion anatomy fits within the distributed functional networks that normally mediate music perception.

### Pitch: interval

The components of pitch perception have been widely studied in both the symptom-led and lesion-led literature that concerns disorders of musical listening. Deficits in the analysis of pitch intervals (the detection of a pitch change and/or the discrimination of the direction of a pitch change) are most strongly associated with lesions involving lateral HG and non-primary auditory cortical areas in PT and the parieto-temporal junction (Fig. 4). The detection of pitch differences and the discrimination of pitch direction are functionally separable, but have been distinguished only infrequently in symptom-led studies. Where it has been specifically assessed, impaired pitch-difference detection is generally associated with involvement of subcortical structures and ascending auditory pathways or PAC in medial HG (Habib *et al.*, 1995; Tramo *et al.*, 2002; Hattiangadi *et al.*, 2005; Terao *et al.*, 2005) while impaired pitch-direction discrimination is generally associated with involvement of lateral HG (Lechevalier *et al.*, 1984; Tanaka *et al.*, 1987; Tramo *et al.*, 2002; Terao *et al.*, 2005).

These data are congruent with evidence from temporal lobectomy series (Supplementary Table 2). Right-lateral HG resection leads to deficits in the detection of pitch change direction in pure tones (Johnsrude *et al.*, 2000) and complex tones (Zatorre, 1988). These findings, especially the latter, suggest that aspects of pitch perception, as opposed to the sensory representation of frequency- and time-domain properties of the stimulus, depend on the integrity of cortical areas beyond PAC. This is consistent with the concept of a 'pitch centre' in lateral HG that emerges from functional imaging of the normal musical brain.

### Pitch: pattern

Deficits in the analysis of pitch patterns, like melodies, comprising multiple notes, are common in acquired disorders of musical listening (Supplementary Table 1). The deficits are most often associated with lesions posterior to HG, in PT and the parieto-temporal junction, and anterior to HG in anterior STG (Figs 3 and 4). The occurrence of such a deficit is more common following right-sided rather than left sided lesions. Melody discrimination has also been widely assessed in the lesion-led literature (Supplementary Table 2): right but not left temporal lobectomy impairs discrimination of pitch pattern, even where HG is not included (Milner, 1962). However, inclusion of HG produces deficits in melody perception over and above those due to the resection of the temporal lobe anterior to it (Zatorre, 1985; Samson and Zatorre, 1988). In a study comparing resections involving posterior versus anterior STG (Liegeois-Chauvel *et al.*,

1998), posterior resection was associated with more severe impairment of pitch pattern perception; this effect could not be attributed to involvement of HG. Right anterior temporal lobe resections have also been associated with impaired working memory for pitch (Zatorre and Samson, 1991), which is likely to affect perception of long-term structure in melodies, and more specifically, discrimination tasks requiring comparisons between sequential stimuli.

Pitch contour (the pattern of ‘ups’ and ‘downs’ in a melody) and the actual pitch values can be considered as corresponding to psychologically distinct ‘global’ and ‘local’ levels of pitch processing, respectively (Dowling and Harwood, 1985). These levels can be probed by tasks which require discrimination of melodies with different pitch contour (‘global’ tasks) or different actual pitch values with the same contour (‘local’ tasks), respectively. The local tasks are often also referred to as interval tasks, as both the absolute value of notes and the intervals before and after them are changed. A ‘pure’ global task would require transposition between the melodies compared (like a shift in key) to prevent the use of any local information. However, this renders the task much harder for non-musicians and the MBEA does not employ it. That different sites of brain damage may differentially affect the use of local and global information in melodies was first demonstrated by Peretz (1990) who showed that patients with right cerebral hemisphere strokes could assess neither global nor local information in melodies, while patients with strokes involving the left hemisphere could use global but not local information. Isolated impairments of local processing were observed, but isolated impairments of global processing were not, leading Peretz to propose an influential hierarchical model of co-operation between the hemispheres. According to this model, the right hemisphere derives pitch contour, which is then elaborated upon by the left hemisphere which fills in the detailed pitch structure. In the model, prior contour processing is necessary for actual pitch values to be processed: lesions involving the right hemisphere therefore compromise the processing of both contour and the actual pitch values whereas lesions involving the left hemisphere prevent actual pitch values being added to the contour provided by the right hemisphere. This model was supported by the findings of a temporal lobectomy series (Liegeois-Chauvel *et al.*, 1998). In this series, isolated deficits of pitch interval processing were observed with resections of right or left anterior temporal cortex, whereas deficits of both contour and interval processing were associated with resections of right temporal cortex, and no isolated deficits of contour processing were found. However, other evidence suggests that the hierarchical co-operativity model should be qualified. Schuppert *et al.* (2000) found that patients with left hemisphere damage were impaired in the use of both local and global information, although isolated deficits in the use of contour information were not observed.

Taken together, these studies build on evidence from functional imaging and suggest that a critical substrate for

analysis of the direction of pitch change is located in right-lateral HG. The analysis of pitch direction in adjacent notes can be considered as a building block for contour in sequences of notes, which in turn may be a necessary step in the analysis of local-pitch information. In the symptom-led studies shown in Fig. 4 the analysis of pitch pattern involves right temporal areas beyond HG, whilst the lesion-led work suggests co-operativity between the hemispheres to process local and global aspects of that pattern. The data are broadly congruent with functional imaging studies of normal subjects showing distributed activation beyond HG when subjects are presented with pitch sequences as opposed to monotonous pitch (Patterson *et al.*, 2002). The functional imaging literature has not yet systematically addressed local and global analysis.

### Pitch: tonal structure

Few clinical studies have addressed the analysis of tonal structure as a specific component of musical listening. Tonal structure refers to rule-based patterns of pitch determined by key. While both tonal and atonal pitch patterns exhibit global and local structure, tonal structure is specific to tonal music (i.e. most Western music composed before the twentieth century). The most widely used test of this type of processing is the scale task in the MBEA, which assesses the ability of subjects to detect notes that are out of key. Deficits in tonal analysis have been associated with damage involving a predominantly right-sided network of non-primary auditory cortical areas including lateral HG, PT, parieto-temporal junction, insula, anterior STG and frontal operculum (Fig. 4). The frontal opercular involvement is proportionately greater than other aspects of pitch processing, but the number of studies is small. Functional imaging of neurologically normal individuals suggests a particular involvement of the frontal lobes in tonal analysis, but the studies are based on different techniques and show different loci for frontal lobe involvement (Janata *et al.*, 2002; Koelsch and Siebel, 2005).

### Timbre

Timbral perception has a number of dimensions that can be related to different acoustic properties of the incoming sound, and lesions affecting any or all of these dimensions could in principle lead to a deficit of timbre perception. Many clinical studies include reports of perceptual alterations in the perceived quality of music (often described as unpleasant, ‘flat’ or ‘mechanical’ in nature) or inability to recognize musical instruments, which might represent specific defects of timbre perception. However, timbre as a distinct functional component of music has only been assessed infrequently in the clinical literature (Supplementary Tables 1 and 2). This evidence suggests that a network of areas in the right superior-temporal lobe that overlaps closely with areas implicated in pitch pattern analysis is critical for normal timbre perception (Fig. 4). Timbral deficits have generally been observed in conjunction with pitch pattern

deficits (Supplementary Table 1); however, timbral deficits with spared pitch pattern perception have also been described after strokes involving right STG (Kohlmetz *et al.*, 2003; Mazzucchi *et al.*, 1982). The deficits may extend to the discrimination of timbre in voices and environmental sounds (Mazzucchi *et al.*, 1982).

These findings from the symptom-led literature are mirrored by studies of temporal lobectomy series (Supplementary Table 2). Right temporal lobectomy leads to deficits in the perception of timbral change when this is in the spectral dimension (Milner, 1962; Samson and Zatorre, 1994), temporal dimension (Samson and Zatorre, 1994), or both (Samson *et al.*, 2002). This last study also suggested a subtle effect of left temporal lobectomy deficit on the processing of timbre associated with melodies but not single notes.

The pre-eminence of non-primary auditory cortical areas in timbre processing and the close relation between timbre and pitch perception is supported by emerging evidence from normal functional imaging studies (Menon *et al.*, 2002; Warren *et al.*, 2005). The analysis of particular dimensions of timbre is a clear direction for future studies of individual patients (Kohlmetz *et al.*, 2003).

### Temporal structure: time interval, rhythm and metre

Like pitch perception, the perception of timing information in music can be analysed hierarchically: the lowest level of temporal processing that we consider here corresponds to the detection of simple durational differences in a tone or detection of a silent interval between two tones. These basic timing elements can be built into more complex structures embedded in metre and rhythm. Schuppert *et al.* (2000) propose a hierarchal scheme where metre and rhythm can be considered as global and local properties in the time-domain. The symptom-led evidence implicates predominantly right-sided non-primary auditory cortical areas posterior to HG in the perception of time interval differences, and bilateral areas widely distributed beyond HG in the perception of rhythm (Fig. 4). Evidence from lesion-led studies broadly supports a bilateral organization: impaired durational processing has been described following right temporal lobectomy (Milner, 1962) and impaired gap detection following left temporo-parietal strokes (Robin *et al.*, 1990). Impaired detection of rhythmic violations has been described in left temporo-parietal stroke (Robin *et al.*, 1990) and left hippocampal sclerosis (Samson *et al.*, 2001), while other studies have not demonstrated laterality differences (Shapiro *et al.*, 1981; Peretz, 1990; Schuppert *et al.*, 2000). At least some of these apparent discrepancies in lateralization may reflect task effects: for example, the detection of rhythmic errors in familiar tunes (Prior *et al.*, 1990; Samson *et al.*, 2001) may require musical processing that is not required for the discrimination of simple rhythmic patterns.

Comparatively few studies of metrical processing have been conducted and evidence for a critical brain substrate

remains inconclusive. This is likely to be due at least in part to the difficulty of assessing metre reliably, particularly in subjects without formal musical training. In the small symptom-led literature, impairments of metre perception have been associated with individual lesions widely distributed in both cerebral hemispheres (Fig. 3). This pattern has been echoed in lesion-led studies. In temporal lobectomy series, Liegeois-Chauvel *et al.* (1998) found metrical impairments following left and right anterior temporal lobe resections, while Kester *et al.* (1991) found a specific decrement in performance following right but not left anterior temporal resection. Neither Ayotte *et al.* (2000) nor Peretz (1990) found stroke patients with heterogeneous left and right hemisphere strokes to be impaired relative to neurologically normal control subjects, while Schuppert *et al.*, (2000) found that both left and right hemispheric stroke patients were impaired relative to controls.

Though still tentative, the clinical evidence suggests a convergence with functional imaging data in healthy subjects, at least in terms of the overlap between the processing mechanisms within the domains of pitch and temporal structure (Griffiths *et al.*, 1999). It is striking that no lesion studies included in our review have implicated the cerebellum in disorders of rhythm, since functional imaging studies (Mathiak *et al.*, 2004) and work in cerebellar patients (Mangels *et al.*, 1998; Harrington *et al.*, 2004) suggest a role for the cerebellum in temporal processing. This may reflect selection bias, since all cases included in our review were required to incorporate a 'systematic and objective evaluation of musical listening' and patients presenting with a timing deficit may be less likely to be tested for other aspects of musical listening, compared with patients presenting with deficits in the pitch domain.

### Memory: familiar and novel material

Impaired recognition of familiar tunes is described in a number of studies (Lechevalier *et al.*, 1984; Peretz *et al.*, 1994, 1998; Griffiths *et al.*, 1997; Johannes *et al.*, 1998; Peretz and Gagnon, 1999; Ayotte *et al.*, 2000; Piccirilli *et al.*, 2000; Wilson *et al.*, 2002; Satoh *et al.*, 2005). In all these cases, recognition problems were accompanied by impaired pitch-pattern perception. However, perception and recognition can sometimes dissociate. Patients may have intact perception but impaired recognition (Eustache *et al.*, 1990 (case 1); Peretz, 1996) or the converse (Eustache *et al.*, 1990 (case 2); Schuppert *et al.*, 2000). The presence of intact perception with impaired recognition also occurs in visual disorders, where that dissociation has been termed associative (as opposed to apperceptive) agnosia (Lissauer, 1890). By analogy with models for vision, apperceptive amusia could arise from abnormal perception of incoming musical material, whereas associative amusia could arise from abnormal association of normally perceived music with stored representations. Cases of abnormal perception of music in the presence of normal recognition of familiar



tunes are not predicted by hierarchical models of normal function, where perception precedes association. The dissociation may be explained by the presence of multiple cues that can lead to recognition of familiar tunes that allow deficits in particular domains to be overcome.

Figs 3 and 4 demonstrate that deficits in the perception and recognition of familiar tunes may occur with damage in either cerebral hemisphere involving the anterior STG and insula (Lechevalier *et al.*, 1984; Peretz *et al.*, 1994, 1998; Peretz and Gagnon, 1999; Satoh *et al.*, 2005). In the lesioned literature, familiar-tune recognition was found to be deficient specifically in association with damage involving the right insula (Ayotte *et al.*, 2000).

Impaired recognition of novel material is tested in the incidental memory test from the MBEA, which assesses implicit encoding and retrieval of novel musical material. Clinical impairments of musical incidental memory are associated with damage involving a bilateral network of areas that closely overlaps the network implicated in the recognition of familiar tunes (Fig. 4), and extends into left middle and inferior temporal cortex. In temporal lobectomy series, incidental memory deficits have been described following both right and left anterior resections (Zatorre, 1985; Samson and Zatorre, 1992).

## Emotion

Most people listen to music purely for the aesthetic pleasure it brings. A loss of enjoyment in musical listening is a common presenting complaint in clinical disorders of musical listening (Supplementary Table 1). In many cases, this loss of pleasure is accompanied by a perceptual derangement: ‘like an out of tune child’s dulcimer’ (Griffiths *et al.*, 1997), ‘mechanical’ (Griffiths *et al.*, 2006) or ‘instruments [may lose] their distinctive features of timbre and sound dull’ (Piccirilli *et al.*, 2000). Associated impairments of pitch pattern perception (Habib *et al.*, 1995) and generalized auditory agnosia (Mazzucchi *et al.*, 1982) have been documented. The most consistent association of altered emotional response to music across studies is damage involving the right posterior temporal lobe and insula (Fig. 4). However, few clinical studies have specifically assessed musical emotion.

Just as perception and recognition for musical material may dissociate, so too may perception and emotional response to music. Isolated deficits of musical emotional response have been described: the patient of Griffiths *et al.* (2004) had been used to experiencing an emotional transformation while listening to Rachmaninov preludes (the ‘shiver down the spine’ phenomenon) but this was lost following an infarction involving left amygdala and insula. In a temporal lobectomy series (Gosselin *et al.*, 2005), patients who had undergone resections of the left or right medial temporal lobe, including the amygdala but sparing the STG, found fearful music less scary than a group of matched controls. Conversely, intact emotional response despite impaired music perception has also been observed (Lechevalier *et al.*, 1984; Peretz *et al.*, 1998; Peretz and Gagnon, 1999). The

patient of Peretz *et al.* (1998) still derived pleasure from music, and was able to classify tunes as happy or sad and to discriminate tunes based on emotional tone despite severe perceptual and recognition impairments.

These findings are consistent with the emerging functional imaging evidence in neurologically normal individuals implicating the insula and amygdala as crucial mediators of the emotional response to music as for other kinds of affective stimuli (Blood *et al.*, 1999; Blood and Zatorre, 2001). However, the complex nature of the emotional dimension in music makes it necessary for clinical studies to adopt more sophisticated methodologies derived from basic neuroscience in order to dissect apart the critical brain substrates for musical emotion. There may be a hierarchy of emotional responses analogous to those identified for pitch and temporal information: the perception of sounds as consonant and dissonant is universal in Western culture, whilst the subject-specific associative phenomenon of ‘shiver’ may be considered to be an aspect of emotion which is context dependent.

## Developmental disorders of musical listening

Case reports of lifelong tone-deafness go back more than a century, but it has only been in the last five years that the condition has undergone systematic investigation using the same tools that have been applied to acquired disorders of musical listening. The disorder was first characterized in this way by Peretz and colleagues using the MBEA and given the label ‘congenital amusia’ (Ayotte *et al.*, 2002). This term emphasises the disorder as a true perceptual agnosia, in which the perception of music is abnormal in the presence of normal hearing and otherwise preserved cognition. Interestingly, the symptom that leads to the initial identification of such subjects is often an inability to sing (usually picked up by their friends and relatives rather than the subjects themselves). However, the systematic studies below consistently demonstrate musical perceptual abnormalities. It remains unclear whether the disorder is homogeneous or whether it has more than one underlying basis. Deficits in the pitch domain are most striking, but variable, whilst the presence of abnormality in other domains is not a consistent finding.

## Pitch

Formal characterization of musical perception using the MBEA (Ayotte *et al.*, 2002) demonstrates consistent deficits in the domain of pitch-pattern perception (pitch contour, actual pitch value and key structure). Our group (Foxton *et al.*, 2004) has carried out tests in which processing of basic pitch patterns are assessed. The group of subjects identified as having amusia using the MBEA and criteria of Peretz were found to have abnormal perception of pitch change and pitch direction, the most striking changes being demonstrated for pitch direction. Most subjects in the amusic

group had thresholds for the identification of pitch direction that were well above a semitone (the normal threshold is a fraction of a semitone) and likely relevant to the perception of Western music. Given that pitch direction can be thought of as a ‘building block’ for contour (the pattern of ‘ups’ and ‘downs’ in a melody), this work suggests a fundamental deficit in pitch processing that is below the level of melody processing. However, the presence of such a causative deficit would predict that the deficit could be overcome by creating melodic sequences with large intervals. The fact that this is not the case (Foxtan *et al.*, 2004) argues against a simple low-level deficit in pitch direction as a single causal mechanism for melodic deficits in amusia. However, it remains possible that an inability to analyse pitch direction leads to a failure to develop normal pitch pattern perception even in the presence of large intervals (i.e. a two-stage mechanism).

A question that arises immediately is whether deficits in pitch contour analysis extend to the ‘melody of speech’ (Monrad-Krohn, 1947), which is one aspect of prosody. In normal speech, pitch contour allows us to understand the difference between phrases that are statements and phrases that are questions. It also conveys emotional emphasis and the characteristics of regional accents. Although, a number of cases of disordered perception of pitch contour in speech have been found in association with acquired amusia, developmental amusia subjects have not been found to have such deficits. When required to discriminate sentences that differed in their intonation, amusics were found to perform as well as controls. However, when the phrases were replaced by sequences of discrete notes that matched the mean pitch of each syllable (Ayotte *et al.*, 2002) or a continuous pitch ‘track’ matched to the speech (Patel *et al.*, 2005), amusic subjects could not perceive the difference. Peretz and Hyde (2003) originally suggested that the preservation of this aspect of prosody in speech was due to the larger pitch changes in speech compared to Western music. The data based on ‘extracted’ pitch contour (Ayotte *et al.*, 2002 and Patel *et al.*, 2005) do not allow such a straightforward interpretation. One possibility is that the amusic subjects can achieve normal performance on the intonation task by relying on cues other than pitch contour, such as intensity differences.

### Temporal structure

Aside from the problem with singing, subjects with amusia can have problems with ‘following the beat’ and with dancing, consistent with a deficit in the processing of metre and rhythm. In ‘The Motorcycle Diaries’, Che Guevara (a noted amusic) dances a tango while those around him dance a lively mambo (Guevara, 2003). Hyde and Peretz (2003) found that although subjects with congenital amusia had a deficit in detection of pitch changes in an otherwise monotonic sequence, their detection of a change in the timing of a note in an otherwise regular sequence was normal. A subsequent study in a different group of amusics (Foxtan *et al.*, 2006) replicated the finding of normal detection of

timing deviation within simple rhythms, but showed that when subjects were required to detect the same deviation in a melodic, as opposed to monotonic context, their performance was impaired. The results support a model in which the abnormal perception of pitch pattern in amusia also affects the perception of the temporal structure of music. The result is interesting in view of studies of acquired amusia (Peretz and Kolinsky, 1993) suggesting that the brain mechanisms for melodic and rhythmic analysis are separable up to a certain point, after which they interact.

### Emotion

The emotional processing of music in subjects with developmental amusia is an issue which is ripe for investigation. Our experience is that this group of individuals exhibits considerable individual variation with respect to this. Subjects demonstrated to have the same perceptual deficits with the MBEA can either enjoy music or find it unpleasant: one subject described Rachmaninov’s second piano concerto as ‘like a banging or noise’. The dissociation between the perception of music and its emotional effect is consistent with evidence from normal functional imaging and clinical studies of acquired lesions (Supplementary Table 1) that strongly suggest distinct substrates. However, the basis for such individual variation is unknown.

### Neural substrate

The brain basis for congenital amusia has not been extensively investigated. In general these individuals do not have a history of neurological damage, and structural brain imaging using MRI reveals no gross structural differences. The technique of voxel-based morphometry allows structural MRI data from two or more groups of individuals (e.g. amusic versus non-amusic individuals) to be interrogated with regard to potential regional differences in grey and white matter density. A recent study demonstrated changes in white matter density in the inferior right frontal lobe (Hyde *et al.*, 2006) and EEG studies of responses to pitch changes (Peretz *et al.*, 2005) have demonstrated normal N1 responses to tones but abnormal N2-P3 responses at longer latency. The N1 response arises from the PT whilst the longer latency responses have a number of more distributed generators. Congruent with the work based on structural MRI, this work suggests brain abnormalities in amusia that may occur in areas distinct from auditory cortex.

Further studies will be required to ascertain the locus and nature of the abnormality in these developmental cases. A straightforward prediction regarding this disorder would be that one or more of the key nodes of the musical listening network have failed to develop normally (Fig. 4 would suggest superior-temporal cortex and areas including the insula and frontal lobe as candidate regions) but an alternative prediction, which can be tested with MRI techniques, such as diffusion tensor imaging and dynamic causal

modelling, would be that the abnormality lies in the connections between these critical nodes.

### Prevalence and genetics

Using a screening test called the Distorted Tunes Test, which tests the perception of key violation, the prevalence of congenital amusia has been estimated to be ~5% (Kalmus and Fry, 1980). A recent study of undergraduates by Cuddy *et al.*, (2005) showed that those students who declared themselves to be tone-deaf scored similarly on the MBEA to a group of students who did not. This is perhaps unsurprising: the label tone-deaf is colloquially used to describe those who cannot sing in tune. Although up to 15% of the population report difficulties in singing in tune, the majority of these people can perceive music normally. People with amusia form a subgroup of out-of-tune singers. Because of their perceptual difficulties, they are not necessarily aware that they sing out-of-tune and would be less likely to self-label as tone deaf compared with people who have singing difficulties but are perceptually normal. This is congruent with our observation that subjects are often referred by their relatives, without being aware of the problem themselves.

Studies of concordance rates in twins suggest that musical listening has a high degree of heritability. Drayna *et al.* (2001) studied performance on the Distorted Tunes Test in monozygotic and dizygotic twins and estimated that between 70 and 80% of performance variance could be accounted for by genetic differences. However, it is currently not known whether congenital amusia captures those individuals at the low end of the musical listening ability spectrum or whether it is a categorically distinct condition. Familial cases are common and autosomal dominant inheritance with incomplete penetrance has been suggested (Kalmus and Fry, 1980).

### Other forms of aberrant musical listening

The preceding sections considered disorders that can be characterized as deficits in musical listening. This section considers what might be thought of as exuberant musical listening: musical perception occurring inappropriately as a result of sound input or in the absence of sound input. An example of the former phenomenon is musical palinacousis: the continued perception of music after the music has stopped. The latter description defines musical hallucinations.

### General comments

Musical hallucinations have been reported from a number of perspectives (including those of audiology, neurology and psychiatry) and the perspective adopted will bias the case description and interpretation. No studies of unbiased populations are available, and few studies have carried out a systematic and thorough assessment of auditory function, neurological and psychiatric status. The studies that have been carried out to examine brain substrate, mainly in the population with deafness, suggest a neural correlate of the hallucinations in brain networks including the superior-temporal lobes. Aetiological theories often focus on single factors, but the case reports reveal a number of patients with co-existent factors that might be relevant.

### Musical hallucinations associated with deafness

Table 3 lists published cases of musical hallucinations and Supplementary Table 3 characterises the features of the patients described. The most common associated factor is acquired deafness, usually in subjects in middle to later life and more commonly in women. We have now assessed

**Table 3** Musical hallucination reports

Agrawal and Sherman (2004)	Fisman (1991)	Nagaratnam <i>et al.</i> (1996)
Aizenberg <i>et al.</i> (1986)	Fukunishi <i>et al.</i> (1998a)	Nevins (1991)
Aizenberg <i>et al.</i> (1991)	Fukunishi <i>et al.</i> (1998b)	Paquier <i>et al.</i> (1992)
Ali (2002)	Fukunishi <i>et al.</i> (1999)	Patel <i>et al.</i> (1987)
Allen (1985)	Gertz <i>et al.</i> (1996)	Raghuram <i>et al.</i> (1980)
Baba <i>et al.</i> (2003)	Gilbert (1993)	Roberts <i>et al.</i> (2001)
Berrios (1990)	Gilchrist and Kalucy (1983)	Ross <i>et al.</i> (1975)
Cascino and Adams (1986)	Griffiths (2000)	Rozanski and Rosen (1952)
Cerrato <i>et al.</i> (2001)	Hammeke <i>et al.</i> (1983)	Saba and Keshavan (1997)
Clark (1998)	Hecaen and Ropert (1959)	Schielke <i>et al.</i> (2000)
Cole <i>et al.</i> (2002)	Hermesh <i>et al.</i> (2004)	Schiffter and Straschill (1977)
Couper (1994)	Inzelberg <i>et al.</i> (1993)	Steinberg <i>et al.</i> (1998)
Curtin and Redmund (2002)	Izumi <i>et al.</i> (2002)	Stricker and Winger (2003)
Douen and Bourque (1997)	Kasai <i>et al.</i> (1999)	Tanriverdi <i>et al.</i> (2001)
Erkwoh <i>et al.</i> (1993)	Keshavan <i>et al.</i> (1988)	Terao (1995)
Evers <i>et al.</i> (2002)	Lennox (1988)	Terao and Tani (1998)
Fenelon <i>et al.</i> (1993)	Miller and Crosby (1979)	Vallada and Gentil (1991)
Fenton and McRae (1989)	Moore (2003)	Warner and Aziz (2005)
Fernandez <i>et al.</i> (1998)	Mori <i>et al.</i> (2006)	Warren and Schott (2006)
Fischer <i>et al.</i> (2004)	Murata <i>et al.</i> (1994)	

See Supplementary Table 3 for comprehensive description of reports.

>20 subjects in this category. Where the audiology data are specified, subjects usually have moderate to severe deafness, but the onset of this can be acute or gradual. Prevalence has been estimated at 2.5% in the deaf elderly attending an audiology clinic (Cole *et al.*, 2002). Subjects usually complain of hearing familiar tunes, such as popular songs and hymns (Griffiths, 2000; Warner and Aziz, 2005). The musical experience is usually a ‘coherent whole’ in that a formed percept with melody and rhythm, with or without lyrics, is experienced. When the subjects are profoundly deaf and unable to hear music normally the hallucinations are often experienced in the same way as normal music before the onset of acquired deafness. The percept can evolve from tinnitus, and one of our subjects described an intermediate type of percept based on a succession of ‘buzzy’ pitches that formed a melody. More commonly, however, subjects experience normal musical instruments and voices. Associated palinacousis is common. The most striking feature of the phenomenon is its salience: the majority of subjects that we have seen describe a percept that is so vivid that they initially feel there is actual music playing in the room. With time, however, subjects generally come to attribute the problem to the ears or the brain, and there is generally no associated delusional system. A number of treatment strategies have been employed, but in our experience the only way to help is to improve hearing via amplification.

The basis for musical hallucinosis in the deaf is not fully established. Cases with evolution from tinnitus suggest a possible basis in the cochlea, which has been proposed by Gordon (1997) as a universal explanation for musical hallucinations. The phenomenology of musical hallucinations, especially the perception of complex-patterned sequences and the consistency with previous listening experience, strongly suggest the involvement of central mechanisms. Griffiths (2000) suggested a mechanism based on amplified musical imagery, where the decreased signal-to-noise ratio in auditory transmission in the deaf leads to the inappropriate activation of cortical networks usually involved in perception and imagery. This model can be characterized as an amplification of normal imagery that is usually suppressed by auditory input. However, a model based on deafness and normal central processing cannot account for the fact that only a small proportion of subjects with moderate or severe deafness develop the disorder. In our experience, vascular risk factors other than old age are over-represented, whilst a number of the patients in Supplementary Table 3 have comorbid psychiatric disease.

Studies that examine brain activity during hallucinations have shown increased activity within the network of areas demonstrated to be active during normal musical perception. Griffiths (2000) showed bilateral perfusion increases in anterior and posterior temporal lobes, frontal opercula and cerebellum in a group PET study of four subjects. Kasai *et al.* (1999) showed increased perfusion in right anterior superior-temporal lobe and right frontal operculum using

SPET (single positron emission tomography) in one subject, in addition to bilateral alteration in the N100m neuromagnetic responses that arise from the posterior superior-temporal lobes. These studies support the idea that the phenomenon in the deaf is associated with activity in the normal brain networks that are active during musical perception and imagery.

### **Musical hallucinations associated with neurological disorder**

Cases of musical hallucinations where a single neurological mechanism is likely to be causative are rarer than the cases in association with deafness. Supplementary Table 3 describes hallucinations associated with lesions in the brainstem or right or left cerebral hemispheres. Berrios (1990) has emphasized abnormality of the right hemisphere, which, in the reported cases, is more commonly affected than the left. If the cases are associated with epileptic foci, the phenomenology of the hallucinations may include experiential features that are not a feature of cases associated with deafness. Cases of musical hallucinations in association with degenerative disorders are rare, although they have been described in association with dementia. In one such case, Mori *et al.* (2006) reported increased perfusion measured with SPET in the left temporal lobe and angular gyrus of a patient with Alzheimer’s disease. A number of other reports have described musical hallucinations associated with the acute use of centrally acting drugs (see Supplementary Table 3).

### **Musical hallucinations associated with psychiatric disorder**

Auditory musical hallucinations in psychiatric populations are rarer than auditory verbal hallucinations. The phenomenon has been described in association with depression, schizophrenia, obsessive-compulsive disorder and alcoholism. Berrios (1991) argued that psychosis and personality traits are not important predisposing factors, and Fukunishi *et al.* (1998a) found a prevalence rate of only 0.2% (six patients) in a population of 3578 general psychiatry inpatients (three of these patients were deaf). In contrast, Hermesh *et al.* (2004) reported a lifetime prevalence of musical hallucinations of 20% in a population of 190 psychiatric outpatients. A particularly high rate (40%) was found in obsessive-compulsive disorder.

Robert Schumann suffered musical hallucinations as part of a psychotic illness. In 1854, he initially experienced a simple pitch (the note ‘A’), which evolved into ‘magnificent music, with instrument of splendid resonance, the like of which has never been heard on earth before’ and which was incorporated in his violin concerto. The grandiose nature of this description suggests bipolar disorder, but there is debate about whether he had neurosyphilis [although there was no clear evidence for this at autopsy (Janisch and Nauhaus, 1986)].



## Conclusion

The aim of this review has been to produce a practical overview of disorders that might be seen in the clinic, rather than to impose a particular theoretical system. However the disorders described above can be understood in terms of the broad principles of normal musical listening that were developed at the start of the review. Normal musical listening involves the rule based analysis of patterns of sound in distributed cortical systems extending well beyond the auditory cortices. Many disorders of musical listening can be understood in terms of altered processing (either deficient or aberrant processing) within these cortical systems.

Considering the variety of pathological processes, lesion locations, assessment tools and premorbid abilities that interact in the disorders of musical listening, the degree of consensus already achieved between clinical and experimental literatures since Critchley and Henson produced their landmark work is remarkable. Nevertheless, many individual patients do not fit the preliminary consensus, and only systematic evaluation of further cases will determine where that consensus should be refined or overturned. This enterprise will be facilitated by the advent of readily available techniques for manipulating and presenting musical stimuli, and analytical methods with which to image the functioning brain and to delineate functional as well as anatomical connections between brain regions. Such techniques provide the opportunity to advance beyond brain mapping and the identification of processing ‘centres’ to more sophisticated and physiologically realistic models based on critical ‘nodes’ in distributed networks with selectivity (rather than exclusivity) for processing particular perceptual and cognitive components of music. The neuroscience of music will benefit from current trends in cognitive neuroscience as a whole: these include improved generic models of complex cognitive functions, a greater appreciation of the role of plasticity and learning in human cognition, and a broader emphasis on the cognitive, affective and social context of music perception alongside the traditional focus on the elementary building blocks of music. The emerging appreciation and understanding of developmental deficits of music perception is likely to become a key theme in the field, complementary to the analysis of acute deficits induced by acquired lesions in previously normal brains. Group studies of developmental amusia should be supplemented by more carefully controlled group studies of acquired musical deficits, by studies that focus specifically on special groups, such as trained musicians, and by prospective studies of phenomena, such as musical training that remain poorly understood.

The clinical neurologist will continue to have a central role in explaining the many remaining discrepancies, and in elucidating the critical roles played by particular brain regions within the distributed networks outlined by functional imaging and other techniques in the healthy brain. We look forward to the further insights that the next thirty years will surely bring.

## Supplementary data

Supplementary data are available at *Brain* Online.

## Acknowledgements

Our work is supported by the Wellcome Trust (L.S., J.D.W. and T.D.G.) and VW Foundation (K.v.K.). J.D.W. received support from an EC grant to the APOPIS Consortium.

## References

- Agrawal AK, Sherman LK. Voriconazole-induced musical hallucinations. *Infection* 2004; 32: 293–5.
- Aizenberg D, Schwartz B, Modai I. Musical hallucinations, acquired deafness, and depression. *J Nerv Ment Dis* 1986; 174: 309–11.
- Aizenberg D, Dorfman-Etrog P, Zemishlany Z, Hermesh H. Musical hallucinations and hearing deficit in a young non-psychotic female. *Psychopathology* 1991; 24: 45–8.
- Ali JA. Musical hallucinations and deafness: a case report and review of the literature. *Neuropsychiatry Neuropsychol Behav Neurol* 2002; 15: 66–70.
- Allen JR. Salicylate-induced musical perceptions. *N Engl J Med* 1985; 313: 642–3.
- Amunts K, Schlaug G, Jancke L, Steinmetz H, Schleicher A, Dabringhaus A, et al. Motor cortex and hand motor skills: structural compliance in the human brain. *Hum Brain Mapp* 1997; 5: 206–15.
- Ashburner J, Friston KJ. Voxel-based morphometry—the methods. *Neuroimage* 2000; 11: 805–21.
- Ayotte J, Peretz I, Rousseau I, Bard C, Bojanowski M. Patterns of music agnosia associated with middle cerebral artery infarcts. *Brain* 2000; 123: 1926–38.
- Ayotte J, Peretz I, Hyde K. Congenital amusia. A group study of adults afflicted with a music-specific disorder. *Brain* 2002; 125: 238–51.
- Baba A, Hamada H, Kocha H. Musical hallucinations in schizophrenia. 2. Relations with verbal hallucinations. *Psychopathology* 2003; 36: 104–10.
- Belin P, Zatorre RJ, Lafaille P, Ahad P, Pike B. Voice-selective areas in human auditory cortex. *Nature* 2000; 403: 309–12.
- Bendor D, Wang X. The neuronal representation of pitch in primate auditory cortex. *Nature*. 2005; 436: 1161–5.
- Bengtsson SL, Nagy Z, Skare S, Forsman L, Forssberg H, Ullen F. Extensive piano practicing has regionally specific effects on white matter development. *Nat Neurosci* 2005; 8: 1148–50.
- Bentley A. Measures of musical abilities. London: NEFR-Nelson; 1985.
- Berrios GE. Musical hallucinations. A historical and clinical study. *Br J Psychiatry* 1990; 156: 188–94.
- Berrios GE. Musical hallucinations: a statistical analysis of 46 cases. *Psychopathology* 1991; 24: 356–60.
- Bever TG, Chiarello RJ. Cerebral dominance in musicians and nonmusicians. *Science* 1974; 185: 537–9.
- Blood AJ, Zatorre R. Intensely pleasurable responses to music correlate with activity in brain regions implicated in reward and emotion. *Proc Natl Acad Sci USA* 2001; 98: 11818–23.
- Blood AJ, Zatorre RJ, Bermudez P, Evans AC. Emotional responses to pleasant and unpleasant music correlate with activity in paralimbic brain regions. *Nat Neurosci* 1999; 2: 382–7.
- Bregman AS. Auditory scene analysis. Cambridge, MA: MIT Press; 1990.
- Brown S, Martinez MJ, Parsons LM. Passive music listening spontaneously engages limbic and paralimbic systems. *Neuroreport* 2004; 15: 2033–7.
- Brust JC. Music and language: musical alexia and agraphia. *Brain* 1980; 103: 367–92.
- Caclin A, McAdams S, Smith BK, Winsberg S. Acoustic correlates of timbre space dimensions: a confirmatory study using synthetic tones. *J Acoust Soc Am* 2005; 118: 471–82.
- Cascino GD, Adams RD. Brainstem auditory hallucinosis. *Neurology* 1986; 36: 1042–7.
- Cerrato P, Imperiale D, Giraudo M, Baima C, Grasso M, Lopiano L, et al. Complex musical hallucinosis in a professional musician with a left

- subcortical haemorrhage. *J Neurol Neurosurg Psychiatry* 2001; 71: 280–1.
- Clark J. Case history of a patient with musical hallucinations and Parkinson's disease. *Int J Geriatr Psychiatry* 1998; 13: 886–7.
- Cole MG, Dowson L, Dendukuri N, Belzile E. The prevalence and phenomenology of auditory hallucinations among elderly subjects attending an audiology clinic. *Int J Geriatr Psychiatry* 2002; 17: 444–52.
- Confavreux C, Croisile B, Garassus P, Aimard G, Trillet M. Progressive amusia and aprosody. *Arch Neurol* 1992; 49: 971–6.
- Couper J. Unilateral musical hallucinations and all that jazz. *Aust NZ J Psychiatry* 1994; 28: 516–9.
- Critchley M, Henson RA, editors. *Music and the brain. Studies in the neurology of music.* London: Heinemann; 1977.
- Cuddy LL, Balkwill L-L, Peretz I, Holden RR. Musical difficulties: a study of 'tone deafness' among university students. *Ann NY Acad Sci* 2005; 1060: 311–24.
- Curtin F, Redmund C. Musical hallucinations during a treatment with benzodiazepine. *Can J Psychiatry* 2002; 47: 789–90.
- Di Pietro M, Laganaro M, Leemann B, Schnider A. Receptive amusia: temporal auditory processing deficit in a professional musician following a left temporo-parietal lesion. *Neuropsychologia* 2004; 42: 868–77.
- Douen AG, Bourque PR. Musical auditory hallucinosis from Listeria rhombencephalitis. *Can J Neurol Sci* 1997; 24: 70–2.
- Dowling WJ, Harwood DL. *Music and cognition.* London: Academic Press; 1985.
- Drayna D, Manichaikul A, de Lange M, Snieder H, Spector T. Genetic correlates of musical pitch recognition in humans. *Science* 2001; 291: 1969–72.
- Erkwoh R, Ebel H, Kachel F, Reiche W, Ringelstein EB, Bull U, et al. 18FDG-PET and electroencephalographic findings in a patient suffering from musical hallucinations. *Nuklear Medizin* 1993; 32: 159–63.
- Eustache F, Lechevalier B, Viader F, Lambert J. Identification and discrimination disorders in auditory perception: a report on two cases. *Neuropsychologia* 1990; 28: 257–70.
- Evers S, Ellger T, Ringelstein EB, Knecht S. Is hemispheric language dominance relevant in musical hallucinations? Two case reports. *Eur Arch Psychiatry Clin Neurosci* 2002; 252: 299–302.
- Fenelon G, Marie S, Ferroir JP, Guillard A. Musical hallucinations: 7 cases. *Rev Neurol (Paris)* 1993; 149: 462–7.
- Fenton GW, McRae DA. Musical hallucinations in a deaf elderly woman. *Br J Psychiatry* 1989; 155: 401–3.
- Fernandez A, Crowther TR, Vieweg WV. Musical hallucinations induced by propranolol. *J Nerv Ment Dis* 1998; 186: 192–4.
- Fischer CE, Marchie A, Norris M. Musical and auditory hallucinations: a spectrum. *Psychiatry Clin Neurosci* 2004; 58: 96–8.
- Fisman M. Musical hallucinations: report of two unusual cases. *Can J Psychiatry* 1991; 36: 609–11.
- Foxton JM, Dean JL, Gee R, Peretz I, Griffiths TD. Characterization of deficits in pitch perception underlying 'tone deafness'. *Brain* 2004; 127: 801–10.
- Foxton JM, Nandy RK, Griffiths TD. Rhythm deficits in 'tone deafness'. *Brain Cogn*, 2006; Epub May 7, 2006.
- Fries W, Swihart AA. Disturbance of rhythm sense following right hemisphere damage. *Neuropsychologia* 1990; 28: 1317–23.
- Friston KJ, Harrison L, Penny W. Dynamic causal modelling. *Neuroimage* 2003; 19: 1273–1302.
- Fujii T, Fukatsu R, Watabe S, Ohnuma A, Teramura K, Kimura I, et al. Auditory sound agnosia without aphasia following a right temporal lobe lesion. *Cortex* 1990; 26: 263–8.
- Fukunishi I, Horikawa N, Onai H. Prevalence rate of musical hallucinations in a general hospital setting. *Psychosomatics* 1998a; 39: 175.
- Fukunishi I, Kitaoka T, Shirai T, Watanabe S. Musical hallucinations after childbirth in a female patient on hemodialysis. *Nephron* 1998b; 79: 105.
- Fukunishi I, Kita Y, Harihara Y, Kubota K, Takayama T, Kawarasaki H, et al. Musical hallucinations after living-donor liver transplantation. *Psychosomatics* 1999; 40: 530–1.
- Gaeb N, Gaser C, Schlaug G. Improvement-related functional plasticity following pitch memory training. *Neuroimage* 2006; 31: 255–63.
- Gaser C, Schlaug G. Brain structures differ between musicians and non-musicians. *J Neurosci* 2003; 23: 9240–5.
- Gertz HJ, Gohringer K, Schimmelpfennig C. Successful carbamazepine therapy of 2 cases of music hallucinations. *Nervenarzt* 1996; 67: 387–9.
- Gilbert GJ. Pentoxifylline-induced musical hallucinations. *Neurology* 1993; 43: 1621–2.
- Gilchrist PN, Kalucy RS. Musical hallucinations in the elderly: a variation on the theme. *Aust NZ J Psychiatry* 1983; 17: 286–7.
- Gordon AG. Do musical hallucinations always arise from the inner ear? *Med Hypotheses* 1997; 49: 111–22.
- Gordon E. *Musical aptitude profile.* Boston: Houghton-Mifflin; 1965.
- Gosselin N, Peretz I, Noulhiane M, Hasboun D, Beckett C, Baulac M, et al. Impaired recognition of scary music following unilateral temporal lobe excision. *Brain* 2005; 128: 628–40.
- Griffiths TD. Musical hallucinosis in acquired deafness. Phenomenology and brain substrate. *Brain* 2000; 123: 2065–76.
- Griffiths TD, Warren JD. The planum temporale as a computational hub. *Trends Neurosci* 2002; 25: 348–53.
- Griffiths TD, Rees A, Witton C, Cross PM, Shakir RA, Green GG. Spatial and temporal auditory processing deficits following right hemisphere infarction. A psychophysical study. *Brain* 1997; 120: 785–94.
- Griffiths TD, Buchel C, Frackowiak RSJ, Patterson RD. Analysis of temporal structure in sound by the human brain. *Nat Neurosci* 1998; 1: 422–7.
- Griffiths TD, Johnsrude I, Dean JL, Green GG. A common neural substrate for the analysis of pitch and duration pattern in segmented sound? *Neuroreport* 1999; 10: 3825–30.
- Griffiths TD, Uppenkamp S, Johnsrude I, Josephs O, Patterson RD. Encoding of the temporal regularity of sound in the human brainstem. *Nat Neurosci* 2001; 4: 633–7.
- Griffiths TD, Warren JD, Dean JL, Howard D. 'When the feeling's gone': a selective loss of musical emotion. *J Neurol Neurosurg Psychiatry* 2004; 75: 344–5.
- Griffiths TD, Warren JD, Jennings AR. Dystimbria: a distinct musical syndrome? In: *Proceedings of the Ninth International Conference for Musical Perception and Cognition, Bologna, Italy, 2006.*
- Grisson B. *Une etude sur les alterations musicales au cours des lesions hemispheriques.* [Thesis]. Paris: University of Paris; 1972.
- Grossman M, Shapiro BE, Gardner H. Dissociable musical processing strategies after localized brain damage. *Neuropsychologia* 1981; 19: 425–33.
- Guevara E. *The motorcycle diaries: notes on a Latin American journey.* New York: Ocean Press; 2003.
- Gutschalk A, Patterson RD, Rupp A, Uppenkamp S, Scherg M. Sustained magnetic fields reveal separate sites for sound level and temporal regularity in human auditory cortex. *Neuroimage* 2002; 15: 207–16.
- Habib M, Daquin G, Milandre L, Royere ML, Rey M, Lanteri A, et al. Mutism and auditory agnosia due to bilateral insular damage - role of the insula in human communication. *Neuropsychologia* 1995; 33: 327–39.
- Hammeke TA, McQuillen MP, Cohen BA. Musical hallucinations associated with acquired deafness. *J Neurol Neurosurg Psychiatry* 1983; 46: 570–2.
- Harms MP, Melcher JR, Weisskoff R. Time courses of fMRI signals in the inferior colliculus, medial geniculate body, and auditory cortex show different dependencies on noise burst rate. *Neuroimage* 1998; 7: S365.
- Harrington DL, Lee RR, Boyd LA, Rapcsak SZ, Knight RT. Does the representation of time depend on the cerebellum? *Brain* 2004; 127: 561–74.
- Hattiangadi N, Pillion JP, Slomine B, Christensen J, Trovato MK, Speedie LJ. Characteristics of auditory agnosia in a child with severe traumatic brain injury: a case report. *Brain Lang* 2005; 92: 12–25.
- Hecaen H, Ropert R. *Ann Med Psychol (Paris)* 1959; 117: 257–306.
- Hermesh H, Konas S, Shiloh R, Dar R, Marom S, Weizman A, et al. Musical hallucinations: prevalence in psychotic and nonpsychotic outpatients. *J Clin Psychiatry* 2004; 65: 191–7.
- Hofman S, Klein C, Arlazoroff A. Common hemisphericity of language and music in a musician. A case report. *J Commun Disord* 1993; 26: 73–82.
- Huber W, Weniger D, Poeck K, Willmes K. The Aachen aphasia test. *Adv Neurol* 1984; 42: 291–303.

- Hutchinson S, Lee LH, Gaab N, Schlaug G. Cerebellar volume of musicians. *Cereb Cortex* 2003; 13: 943–9.
- Hyde KL, Peretz I. 'Out-of-pitch' but still 'in-time'. An auditory psychophysical study in congenital amusic adults. *Ann NY Acad Sci* 2003; 999: 173–6.
- Hyde KL, Zatorre RJ, Griffiths TD, Lerch JP, Peretz I. The brain morphometry of congenital amusic individuals. *Brain* 2006. In press.
- Inzelberg R, Vishnievskaya S, Korczyn AD. Transient musical hallucinosis. *J Neurol Neurosurg Psychiatry* 1993; 56: 833.
- Izumi Y, Terao T, Ishino Y, Nakamura J. Differences in regional cerebral blood flow during musical and verbal hallucinations. *Psychiatry Res* 2002; 116: 119–23.
- Janata P, Birk JL, Van Horn JD, Leman M, Tillmann B, Bharucha JJ. The cortical topography of tonal structures underlying Western music. *Science* 2002; 298: 2167–70.
- Janisch W, Nauhaus G. Autopsy report of the corpse of the composer Robert Schumann - publication and interpretation of a rediscovered document. *Zentralbl Allg Pathol* 1986; 132: 129–36.
- Johannes S, Jorges ME, Dengler R, Munte TF. Cortical auditory disorders: a case of non-verbal disturbances assessed with event-related brain potentials. *Behav Neurol* 1998; 11: 55–73.
- Johkura K, Matsumoto S, Hasegawa O, Kuroiwa Y. Defective auditory recognition after small hemorrhage in the inferior colliculi. *J Neurol Sci* 1998; 161: 91–6.
- Johnsrude IS, Penhune VB, Zatorre RJ. Functional specificity in right human auditory cortex for perceiving pitch direction. *Brain* 2000; 123: 155–63.
- Kalmus H, Fry DB. On tune deafness (dysmelodia): frequency, development, genetics and musical background. *Ann Hum Genet* 1980; 43: 369–82.
- Kasai K, Asada T, Yumoto M, Takeya J, Matsuda H. Evidence for functional abnormality in the right auditory cortex during musical hallucinations. *Lancet* 1999; 354: 1703–4.
- Keshavan MS, Kahn EM, Brar JS. Musical hallucinations following removal of a right frontal meningioma. *J Neurol Neurosurg Psychiatry* 1988; 51: 1235–6.
- Kester DB, Saykin AJ, Sperling MR, O'Connor MJ, Robinson LJ, Gur RC. Acute effect of anterior temporal lobectomy on musical processing. *Neuropsychologia* 1991; 29: 703–8.
- Koelsch S, Siebel WA. Towards a neural basis of music perception. *Trends Cogn Sci* 2005; 9: 578–84.
- Koelsch S, Fritz T, V Cramon DY, Muller K, Friederici AD. Investigating emotion with music: an fMRI study. *Hum Brain Mapp* 2006; 27: 239–50.
- Kohlmetz C, Muller SV, Nager W, Munte TF, Altenmuller E. Selective loss of timbre perception for keyboard and percussion instruments following a right temporal lesion. *Neurocase* 2003; 9: 86–93.
- Lechevalier B, Rossa Y, Eustache F, Schupp C, Boner L, Bazin C. Un cas de surdit, corticale, pargnant en partie la musique. *Rev Neurol* 1984; 140: 190–201.
- Lennox G. Auditory hallucinations due to ear disease. *Br J Psychiatry* 1988; 153: 713–4.
- Levin HS, Rose JE. Alexia without agraphia in a musician after transcalsal removal of a left intraventricular meningioma. *Neurosurgery* 1979; 4: 168–174.
- Levitin DJ, Menon V. Musical structure is processed in 'language' areas of the brain: a possible role for Brodmann area 47 in temporal coherence. *Neuroimage* 2003; 20: 2142–52.
- Lieberman AM, Mattingly IG. The motor theory of speech perception revised. *Cognition* 1985; 21: 1–36.
- Liegeois-Chauvel C, Peretz I, Babai M, Laguittin V, Chauvel P. Contribution of different cortical areas in the temporal lobes to music processing. *Brain* 1998; 121: 1853–67.
- Lissauer H. Ein Fall von Seelenblindheit nebst einem Beitrage zur Theorie derselben. *Arch Psychiatr Nervenkr* 1890; 21: 222–70.
- Logothetis NK, Pauls J, Augath M, Triniath T, Oeltermann A. Neurophysiological investigation of the basis of the fMRI signal. *Nature* 2001; 412: 150–7.
- Luders E, Gaser C, Jancke L, Schlaug G. A voxel-based approach to gray matter asymmetries. *Neuroimage* 2004; 22: 656–64.
- Mangels AR, Ivry RB, Shimizu N. Dissociable contributions of the prefrontal and neocerebellar cortex to time perception. *Brain Res Cogn Brain Res* 1998; 7: 15–39.
- Mathiak K, Hertrich I, Grodd W, Ackermann H. Discrimination of temporal information at the cerebellum: functional magnetic resonance imaging of nonverbal auditory memory. *Neuroimage* 2004; 21: 154–62.
- Mavlov L. Amusia due to rhythm agnosia in a musician with left hemisphere damage: a non-auditory supramodal defect. *Cortex* 1980; 16: 331–8.
- Mazzoni M, Moretti P, Pardossi L, Vista M, Muratorio A, Puglioli M. A case of music imperception. *J Neurol Neurosurg Psychiatry* 1993; 56: 322.
- Mazzucchi A, Marchini C, Budai R, Parma M. A case of receptive amusia with prominent timbre perception defect. *J Neurol Neurosurg Psychiatry* 1982; 45: 644–7.
- McAdams S, Cunible JC. Perception of timbral analogies. *Philos Trans R Soc Lond B Biol Sci* 1992; 336: 383–9.
- McDermott J, Hauser M. The origins of music: innateness, development, and evolution. *Music Percept* 2005; 23: 29–59.
- Mendez MF, Geehan GR. Cortical auditory disorders: clinical and psychoacoustic features. *J Neurol Neurosurg Psychiatry* 1988; 51: 1–9.
- Menon V, Levitin DJ, Smith BK, Lembke A, Krasnow BD, Glazer D, et al. Neural correlates of timbre change in harmonic sounds. *Neuroimage* 2002; 17: 1742–54.
- Miller TC, Crosby TW. Musical hallucinations in a deaf elderly patient. *Ann Neurol* 1979; 5: 301–2.
- Milner B. Laterality effects in audition. In: Mountcastle VB, editor. *Interhemispheric relations and cerebral dominance*. Baltimore: Johns Hopkins University Press; 1962. p. 177–95.
- Monrad-Krohn GH. Dysprosody or altered 'melody of language'. *Brain* 1947; 70: 405–15.
- Moore TA. Musical hallucinations induced by oxycodone. *Am J Geriatr Psychiatry* 2003; 11: 470.
- Mori T, Ikeda M, Fukuhara R, Sugawara Y, Nakata S, Matsumoto N, et al. Regional cerebral blood flow change in a case of Alzheimer's disease with musical hallucinations. *Eur Arch Psychiatry Clin Neurosci* 2006; 256: 236–9.
- Murata S, Naritomi H, Sawada T. Musical auditory hallucinations caused by a brainstem lesion. *Neurology* 1994; 44: 156–8.
- Nagaratnam N, Virk S, Brdarevic O. Musical hallucinations associated with recurrence of a right occipital meningioma. *Br J Clin Pract* 1996; 50: 56–7.
- Nevins MA. Musical hallucinations and triazolam use. *N J Med* 1991; 88: 907–8.
- Paquier P, van Vugt P, Bal P, Cras P, Parizel PM, van Haesendonck J, et al. Transient musical hallucinosis of central origin: a review and clinical study. *J Neurol Neurosurg Psychiatry* 1992; 55: 1069–73.
- Patel AD, Balaban E. Temporal patterns of human cortical activity reflect tone sequence structure. *Nature* 2000; 404: 80–84.
- Patel AD, Peretz I, Tramo M, Labreque R. Processing prosodic and musical patterns: a neuropsychological investigation. *Brain Lang* 1998; 61: 123–44.
- Patel AD, Foxton JM, Griffiths TD. Musically tone-deaf individuals have difficulty discriminating intonation contours extracted from speech. *Brain Cogn* 2005; 59: 310–3.
- Patel HC, Keshavan MS, Martin S. A case of Charles Bonnet syndrome with musical hallucinations. *Can J Psychiatry* 1987; 32: 303–4.
- Patterson RD, Uppenkamp S, Johnsrude IS, Griffiths TD. The processing of temporal pitch and melody information in auditory cortex. *Neuron* 2002; 36: 767–76.
- Penagos H, Melcher JR, Oxenham AJ. A neural representation of pitch salience in nonprimary human auditory cortex revealed with functional magnetic resonance imaging. *J Neurosci* 2004; 24: 6810–15.
- Penhune VB, Zatorre RJ, Evans AC. Cerebellar contributions to motor timing: a PET study of auditory and visual rhythm reproduction. *J Cogn Neurosci* 1998; 10: 752–65.



- Peretz I. Processing of local and global musical information by unilateral brain-damaged patients. *Brain* 1990; 113: 1185–205.
- Peretz I. Can we lose memory for music? A case of music agnosia in a non-musician. *J Cogn Neurosci* 1996; 8: 481–96.
- Peretz I, Kolinsky R. Boundaries of separability between melody and rhythm in music discrimination: a neuropsychological perspective. *Q J Exp Psychol A* 1993; 46: 301–25.
- Peretz I, Gagnon L. Dissociation between recognition and emotion for melodies. *Neurocase* 1999; 5: 21–30.
- Peretz I, Coltheart M. Modularity of music processing. *Nat Neurosci* 2003; 6: 688–91.
- Peretz I, Hyde KL. What is specific to music processing? Insights from congenital amusia. *Trends Cogn Sci* 2003; 7: 362–7.
- Peretz I, Zatorre RJ. Brain organization for music processing. *Annu Rev Psychol* 2005; 56: 89–114.
- Peretz I, Kolinsky R, Tramo M, Labrecque R, Hublet C, Demeurise G, et al. Functional dissociations following bilateral lesions of auditory cortex. *Brain* 1994; 117: 1283–1301.
- Peretz I, Belleville S, Fontaine F. Dissociations entre musique et langage apres atteinte cerebrale; un nouveau cas d'amusie sans aphasie. *Can J Exp Psychol* 1997; 51: 354–68.
- Peretz I, Cagnon L, Bouchard B. Music and emotion: perceptual determinants, immediacy, and isolation after brain damage. *Cognition* 1998; 68: 111–41.
- Peretz I, Blood AJ, Penhune V, Zatorre R. Cortical deafness to dissonance. *Brain* 2001; 124: 928–40.
- Peretz I, Champod A-S, Hyde KL. Varieties of musical disorders. The Montreal battery of evaluation of amusia. *Ann NY Acad Sci* 2003; 999: 58.
- Peretz I, Brattico E, Tervaniemi M. Abnormal electrical brain responses to pitch in congenital amusia. *Ann Neurol* 2005; 58: 478–82.
- Phillips-Silver J, Trainor LJ. Feeling the beat: movement influences infant rhythm perception. *Science* 2005; 308: 1430.
- Piccirilli M, Sciarra T, Luzzi S. Modularity of music: evidence from a case of pure amusia. *J Neurol Neurosurg Psychiatry* 2000; 69: 541–5.
- Plack CJ, Oxenham AJ, Fay RR, Popper AN, editors. *Pitch: neural coding and perception*. New York: Springer Verlag; 2006. In press.
- Price C, Thierry G, Griffiths T. Speech-specific auditory processing: where is it? *Trends Cogn Sci* 2005; 9: 271–6.
- Prior M, Kinsella G, Giese J. Assessment of musical processing in brain-damaged patients: implications for laterality of music. *J Clin Exp Neuropsychol* 1990; 12: 301–12.
- Rademacher J, Morosan P, Schormann T, Schleicher A, Werner C, Freund H-J, et al. Probabilistic mapping and volume measurement of human primary auditory cortex. *Neuroimage* 2001; 13: 669–83.
- Raghuram R, Keshavan MD, Channabasavanna SM. Musical hallucinations in a deaf middle-aged patient. *J Clin Psychiatry* 1980; 41: 357.
- Roberts DL, Tatini U, Zimmerman RS, Bortz JJ, Sirven JJ. Musical hallucinations associated with seizures originating from an intracranial aneurysm. *Mayo Clinic Proc* 2001; 76: 423–6.
- Robin DA, Tranel D, Damasio H. Auditory perception of temporal and spectral events in patients with focal left and right cerebral lesions. *Brain Lang* 1990; 39: 539–55.
- Ross ED, Jossman PB, Bell B, Sabin T, Geschwind N. Musical hallucinations in deafness. *JAMA* 1975; 231: 620–2.
- Rozanski J, Rosen H. Musical hallucinosis in otosclerosis. *Confin Neurol* 1952; 12: 49–54.
- Saba PR, Keshavan MS. Musical hallucinations and musical imagery: prevalence and phenomenology in schizophrenic inpatients. *Psychopathology* 1997; 30: 185–90.
- Sakai K, Hikosaka O, Miyauchi S, Takino R, Tamada T, Iwata NK, et al. Neural representation of a rhythm depends on its interval ratio. *J Neurosci* 1999; 19: 10074–81.
- Samson S, Zatorre RJ. Melodic and harmonic discrimination following unilateral cerebral excision. *Brain Cogn* 1988; 7: 348–60.
- Samson S, Zatorre RJ. Recognition memory for text and melody of songs after unilateral temporal lobe lesion: evidence for dual encoding. *J Exp Psychol Learn Mem Cogn* 1991; 17: 793–804.
- Samson S, Zatorre RJ. Learning and retention of melodic and verbal information after unilateral temporal lobectomy. *Neuropsychologia* 1992; 30: 815–26.
- Samson S, Zatorre RJ. Contribution of the right temporal lobe to musical timbre discrimination. *Neuropsychologia* 1994; 32: 231–40.
- Samson S, Ehrle N, Baulac M. Cerebral substrates for musical temporal processes. *Ann NY Acad Sci* 2001; 930: 166–78.
- Samson S, Zatorre RJ, Ramsay JO. Deficits of musical timbre perception after unilateral temporal lobe lesion revealed with multidimensional scaling. *Brain* 2002; 125: 511–23.
- Satoh M, Takeda K, Murakami Y, Onouchi K, Inoue K, Kuzuhara S. A case of amusia caused by the infarction of anterior portion of bilateral temporal lobes. *Cortex* 2005; 41: 77–83.
- Schielle E, Reuter U, Hoffmann O, Weber JR. Musical hallucinations with dorsal pontine lesions. *Neurology* 2000; 55: 454–5.
- Schlaug G, Jancke L, Huang Y, Staiger JF, Steinmetz H. Increased corpus callosum size in musicians. *Neuropsychologia* 1995a; 33: 1047–55.
- Schlaug G, Jancke L, Huang Y, Steinmetz H. In vivo evidence of structural brain asymmetry in musicians. *Science* 1995b; 267: 699–701.
- Schneider P, Scherg M, Dosch HG, Specht HJ, Gutschalk A, Rupp A. Morphology of Heschl's gyrus reflects enhanced activation in the auditory cortex of musicians. *Nat Neurosci* 2002; 5: 688–94.
- Schuppert M, Munte TF, Wieringa BM, Altenmuller E. Receptive amusia: evidence for cross-hemispheric neural networks underlying music processing strategies. *Brain* 2000; 123: 546–59.
- Seashore CE. *The psychology of musical talent*. Boston: Silver, Burdett and Company; 1919.
- Shankweiler D. Effects of temporal lobe damage on the perception of dichotically presented melodies. *J Comp Physiol Psychol* 1966; 62: 115–9.
- Shapiro BE, Grossman M, Gardner H. Selective musical processing deficits in brain damaged populations. *Neuropsychologia* 1981; 19: 161–9.
- Shiffner R, Strasschill M. Aura continua musicalis - bericht uber einen Krankheitsfall mit sensorischem Status epilepticus. *Nervenarzt* 1977; 48: 321–5.
- Sidtis JJ, Volpe BT. Selective loss of complex-pitch or speech discrimination after unilateral lesion. *Brain Lang* 1988; 34: 235–45.
- Spreen O, Benton AL, Fincham RW. Auditory agnosia without aphasia. *Arch Neurol* 1965; 13: 84–92.
- Steinberg R, Flesch M, Gunther W. Schizophrenic symptoms and the perception of sound. In: Nielzen S, Olsson O, editors. *Clinical psychoacoustics - schizophrenia*. Lund: Lund University Press; 1998.
- Stewart L, Henson R, Kampe K, Walsh V, Turner R, Frith U. Brain changes after learning to read and play music. *Neuroimage* 2003; 20: 71–83.
- Stricker RB, Winger EE. Musical hallucinations in patients with Lyme disease. *South Med J* 2003; 96: 711–5.
- Tanaka Y, Yamadori A, Mori E. Pure word deafness following bilateral lesions. *Brain* 1987; 110: 381–403.
- Tanriverdi N, Sayilgan MA, Ozcurumez G. Musical hallucinations associated with abruptly developed bilateral loss of hearing. *Acta Psychiatr Scand* 2001; 103: 153–5.
- Terao T. Tricyclic-induced musical hallucinations and states of relative sensory deprivation. *Biol Psychiatry* 1995; 38: 192–3.
- Terao T, Tani Y. Carbamazepine treatment in a case of musical hallucinations with temporal lobe abnormalities. *Aust NZ J Psychiatry* 1998; 32: 454–6.
- Terao Y, Mizuno T, Shindoh M, Sakurai Y, Ugawa Y, Kobayashi S, et al. Vocal amusia in a professional tango singer due to a right superior-temporal cortex infarction. *Neuropsychologia* 2005; 44: 479–88.
- Tramo MJ, Bharucha JJ. Musical priming by the right hemisphere post-callosotomy. *Neuropsychologia* 1991; 29: 313–25.
- Tramo MJ, Bharucha JJ, Musiek FE. Music perception and cognition following bilateral lesions of auditory cortex. *J Cogn Neurosci* 1990; 2: 195–212.
- Tramo MJ, Shah GD, Braida LD. Functional role of auditory cortex in frequency processing and pitch perception. *J Neurophysiol* 2002; 87: 122–39.



- Ustvedt HI. Ueber die Untersuchung der musikalischen Funktionen bei Patienten mit Gehirnleiden besonders bei Patienten mit Aphasie. *Acta Med Scand* 1937; 86: 1–186.
- Vallada HP, Gentil V. Musical hallucinations triggered by clomipramine? *Br J Psychiatry* 1991; 159: 888–9.
- Warner N, Aziz V. Hymns and arias: musical hallucinations in older people in Wales. *Int J Geriatr Psychiatry* 2005; 20: 658–60.
- Warren JD, Jennings AR, Griffiths TD. Analysis of the spectral envelope of sounds by the human brain. *Neuroimage* 2005; 24: 1052–7.
- Warren JD, Schott G. Musical hallucinations in a musician. *J Neurol* 2006. In press.
- Warrier CM, Zatorre RJ. Right temporal cortex is critical for utilization of melodic contextual cues in a pitch constancy task. *Brain* 2004; 127: 1616–25.
- Wertheim N, Botez MI. Receptive amusia: a clinical analysis. *Brain* 1961; 84: 19–30.
- Wilson SJ, Pressing JL, Wales RJ. Modelling rhythmic function in a musician post-stroke. *Neuropsychologia* 2002; 40: 1494–505.
- Wood CC. Generators of event-related potentials. In: Halliday VB, Butler SR, Paul R, editors. *A textbook of clinical neurophysiology*. New York: Wiley; 1987. p. 535–67.
- Xu D, Liu T, Ashe J, Bushara KO. Role of the Olivo-Cerebellar System in Timing. *J Neurosci* 2006; 26: 5990–5.
- Zatorre RJ. Pitch perception of complex tones and human temporal lobe function. *J Acoust Soc Am* 1988; 84: 566–72.
- Zatorre RJ, Samson S. Role of the right temporal neocortex in retention of pitch in auditory short-term memory. *Brain* 1991; 114: 2403–17.
- Zatorre RJ, Halpern AR. Effect of unilateral temporal lobe excision on perception and imagery of songs. *Neuropsychologia* 1993; 31: 221–32.
- Zatorre RJ, Evans AC, Meyer E. Neural mechanisms underlying melodic perception and memory for pitch. *J Neurosci* 1994; 14: 1908–19.
- Zatorre RJ, Perry DW, Beckett CA, Westbury CF, Evans AC. Functional anatomy of musical processing in listeners with absolute pitch and relative pitch. *Proc Natl Acad Sci USA* 1998; 95: 3172–7.